

Changes in the histoarchitectonics of the kidneys of experimental rats under the conditions of administration of *Vipera berus nikolskii* viper venom

The aim of the work: to study morphological changes in the kidneys of experimental rats under the conditions of administration of *Vipera berus nikolskii* viper venom.

Materials and Methods. The animals were divided into two groups: control and experimental, each with 10 individuals. Experimental rats received an intraperitoneal injection of a semi-lethal dose (LD_{50}) of *Vipera berus nikolskii* venom in saline, at a concentration of $0.972 \text{ mg}\cdot\text{g}^{-1}$. The control group was administered only saline. After 24 hours, the rats were euthanised by decapitation after anaesthesia. Histological preparations were examined under a SEO SCAN light microscope and recorded using a Vision CCD camera equipped with an image output system.

Results. Histological analysis of the effect of the venom of the viper *Vipera berus nikolskii* on the kidneys demonstrated the presence of big destructive changes in the animal organ. This is due to the powerful combination of venom phospholipases A2 and metalloproteinases, which leads to systemic cytolysis and vasopathy. Total disorganisation of the order of the renal corpuscles, phenomena of glomerular necrobiosis, and desquamation of the outer leaf of the Shumlyansky-Bowman capsule are observed. Pronounced lymphohistioplasmocytic infiltration of the organ parenchyma is noted. Morphological changes in the epithelium of the renal nephron tubules under these conditions have the character of acute necrotic nephrosis.

Conclusions. Intoxication with the venom of the viper *Vipera berus nikolskii* causes the development of acute necrotic nephrosis. There is a transition from dystrophy to coagulative necrosis, with massive karyorrhexis, karyolysis, and the formation of structureless cellular detritus. Multiple extravasations and extensive hemorrhagic foci in the cortical substance are noted.

Key words: venom; snakes; kidneys; inflammation; necrosis; morphology; rats.

Problem Statement and Recent Research

Analysis. Disruption of the hemostasis system, massive bleeding, myonecrosis, dermonecrosis, kidney dysfunction, and other symptoms can lead to disability or death following viper bites [1–4]. Currently, there is established evidence of inflammation development and an imbalance in the antioxidant system caused by viper venom toxins, which are the subject of ongoing comprehensive studies [5–8].

The kidneys require cells with numerous mitochondria to remove metabolic waste from the blood and regulate fluid and electrolyte balance. Mitochondria generate the energy needed for these vital functions and adapt to different metabolic states through various signalling pathways, such as mTOR and AMPK, which activate transcriptional coactivators like PGC1 α . They also help maintain mitochondrial dynamics and bioenergetics, ensuring homeostasis. Mitochondrial dysfunction causes decreased ATP production, cellular impairment, and structural changes in the kidneys [9–12]. There are mechanisms to support mitochondrial function during hypoxia. When oxygen is scarce, ATP production drops, leading

to cell death. Under normal oxygen conditions, HIF1 α is degraded with oxygen and α -ketoglutarate present. In hypoxia, HIF1 α combines with HIF1 β to form a transcription factor that binds to the hypoxia response element (HRE) in genes for glycolytic enzymes and glucose transporters in the kidney [13]. At a cellular level, mitochondrial swelling, fragmentation, reduced ATP production, increased ROS, cytochrome c release, and cristae destruction occur. Reduced ATP and mitochondrial dysfunction are observed in many animal models of acute renal failure, including sepsis, and involve loss of respiratory chain proteins in proximal tubules [14]. Similarly, venomous snake and viper bites can cause kidney ischemia and hypoxia, impairing fatty acid transport and oxidation. This leads to fatty acid accumulation in the cytoplasm, decreased ATP synthesis, and mitochondrial dysfunction due to altered respiratory chain activity [15–17].

The kidneys are highly vulnerable to OS because they have long chains of polyunsaturated fatty acids in their lipid molecules. Viper venom components can cause kidney damage through direct nephrotoxicity or indirect effects like hemolysis and rhabdomyolysis,

which activate OS in multiple phases, leading to permanent kidney injury.

The aim of the work: study of morphological changes in the kidneys of experimental rats under the conditions of administration of *Vipera berus nikolskii* viper venom.

Materials and Methods. Experimental studies involved white male rats with non-linear physiology. After a 7-day acclimatisation period in the animal facility at Taras Shevchenko National University of Kyiv, the animals were maintained under controlled temperature and lighting conditions. They received a standard diet and water. All procedures adhered to the NIH guidelines for laboratory animal care and the European Council Directive (86/609/EEC) of November 24, 1986. The research received approval from the Bioethics Commission of the National Scientific Centre "Institute of Biology and Medicine" of Taras Shevchenko University (protocol No. 2, 08/19/2021) and the Bioethics Committee of National Pirogov Memorial Medical University, Vinnytsya (protocol No. 4, 04/01/2024).

The venom of the viper *Vipera berus nikolskii* was collected at V. N. Karazin Kharkiv National University. The lyophilised native venom was stored at -20 °C and dissolved in saline just before the experiment.

The animals were divided into two groups – control and experimental – with 10 subjects each. The experimental rats received an intraperitoneal injection of a semi-lethal dose (LD_{50}) of *Vipera berus nikolskii* venom in saline at $0.972 \text{ mg} \cdot \text{g}^{-1}$. The control group received only saline. After 24 hours, the rats were euthanised by decapitation following anaesthesia, and their removal from the experiment was completed.

For microscopic examination, kidney samples were collected from all animal groups. The samples were fixed in 10% formalin solution for one day, then dehydrated through increasing alcohol concentrations and embedded in paraffin blocks. Kidney tissues were stained with hematoxylin and eosin for histological analysis. To evaluate fibrous changes and stromal structure, paraffin sections were stained using the Azan trichrome method. Initially, sections were stained with azocarmine G, then differentiated with aniline-alcohol solution for optimal contrast and selective tissue staining. After treatment with phosphomolybdic acid, a final counterstain with aniline blue was applied to visualise collagen fibres.

Histological preparations were examined under an SEO SCAN light microscope and captured with a Vision CCD Camera equipped with an image output system.

Results. Histological analysis of the effect of the venom of the viper *Vipera berus nikolskii* on the kidneys demonstrated the presence of big destructive changes in the animal organ. This fact is due to the powerful combination of venom phospholipases A2 and metalloproteinases, which leads to systemic cytolysis and vasopathy. Total disorganisation of the order of the renal corpuscles is observed. The vascular glomeruli look sharply full-blooded, the capillary loops are dilated and deformed. In a significant part of the corpuscles, glomerular necrobiosis phenomena are noted, since the capillaries lost their clear contours, merging into a homogeneous eosinophilic mass. Swelling of the epithelial lining of the outer leaf of the Shumlyansky-Bowman capsule led to its desquamation, and a large amount of protein precipitate in the urinary space may be evidence of massive proteinuria already in the early stages of intoxication. A characteristic feature is a pronounced lymphohistioplasmacytic infiltration of the organ parenchyma, detected in the interstitium, around the renal corpuscles, and perivascularly. The diffuse nature of the inflammatory infiltration is likely a sign of reactive changes in the organ and of migration of immunocompetent cells to foci of primary damage (Fig. 1).

Morphological changes in the epithelium of the renal nephron tubules under these conditions have the character of acute necrotic nephrosis. Epitheliocytes of the proximal tubules of the nephron are in a state of deep granular and vacuolar dystrophy. In some places, the cytoplasm of individual epithelial cells of the proximal tubules is foamy due to deep disruption of

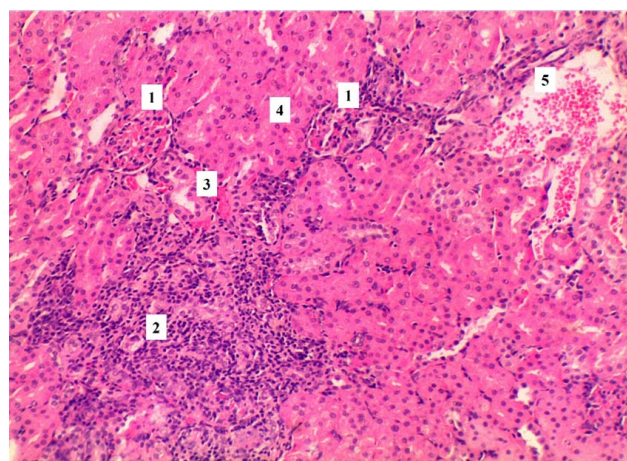


Fig. 1. Morphological organisation of rat kidneys under conditions of intoxication with the venom of the viper *Vipera berus nikolskii*: 1 – Renal corpuscles, 2 – lymphoplasmacytic infiltration, 3 – distal nephron tubules, 4 – proximal nephron tubules, 5 – focus of haemorrhage. Staining with hematoxylin and eosin. $\times 100$.

membrane ion pumps by phospholipases. A characteristic feature of the action of the poison of *Vipera berus nikolskii* is the mosaicism of nuclear changes in epithelial cells. Along with karyopycnosis, karyolysis is observed, with the formation of barely noticeable shadows in place of the nuclei, indicating the irreversible death of epithelial cells. The apical pole in the vast majority of epithelial cells is destroyed, and the brush border is not differentiated (Fig. 2).

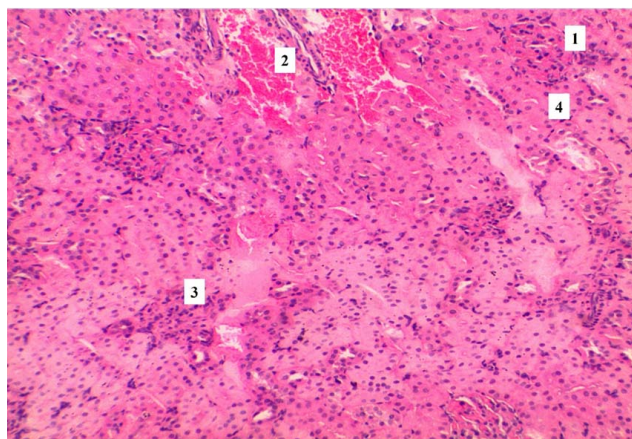


Fig. 2. Histological organisation of rat kidneys under conditions of intoxication with the venom of the viper *Vipera berus nikolskii*: 1 – Shrinkage of the renal corpuscle, 2 – foci of haemorrhage, 3 – destruction of the renal corpuscle, 4 – nephron tubules. Staining with hematoxylin and eosin. $\times 100$.

The distal tubules are dilated due to paralytic dilatation. In their lumens, massive haemoglobin cylinders of dark pink colour are fixed, which is the result of intense intravascular hemolysis, specific for the action of the poison of *Vipera berus nikolskii*. Epitheliocytes of the walls of the distal tubules have a weakly eosinophilic cytoplasm with signs of oedema. The nuclei lose stratification, being located chaotically at different poles of the cells. They are rounded, markedly hyperchromic with a predominance of heterochromatin (Fig. 2).

The walls of the renal arteries and arterioles show signs of fibrinoid oedema. The vascular endothelium undergoes diffuse desquamation into the lumen, which creates the prerequisites for microthrombus formation. Numerous diapedetic and massive focal haemorrhages are detected. Erythrocytes infiltrate the interstitium of the cortical substance, displacing the proximal and distal parts of the nephron tubules, which increases tissue hypoxia (Fig. 3).

The use of the azan staining method under conditions of exposure to the venom of the viper *Vipera berus nikolskii* enabled the detection of deep

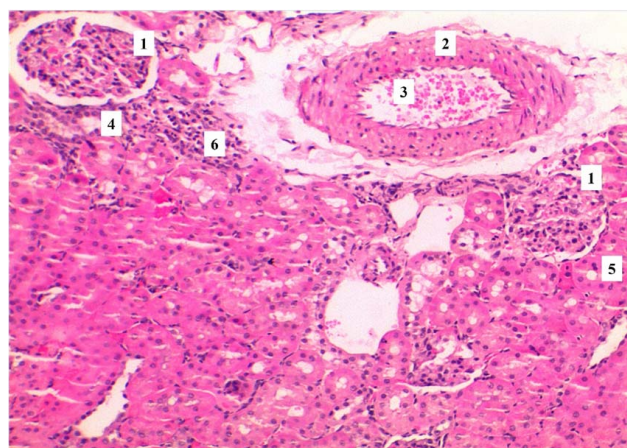


Fig. 3. Histological changes in rat kidneys under conditions of intoxication with the venom of the viper *Vipera berus nikolskii*: 1 – Renal corpuscle, 2 – thickening of the vascular wall, 3 – accumulation of erythrocytes in the lumen of the blood vessel, 4 – distal tubules of the nephron, 5 – proximal tubules of the nephron, 6 – lymphocytic infiltration. Staining with hematoxylin and eosin. $\times 100$.

destruction of components of the filtration barrier, which cannot be fully assessed with standard staining methods. The phenomenon of "melting" of collagen structures is observed: the membranes become blurred and lose their blue colour intensity, indicating enzymatic lysis by venom metalloproteinases. The outer leaf of the capsule shows signs of perifocal oedema (Fig. 4).

The basement membranes of the proximal tubules are also fragmented. In areas of total epithelial necrosis, the blue membrane line completely disappears, resulting in the fusion of the tubule walls

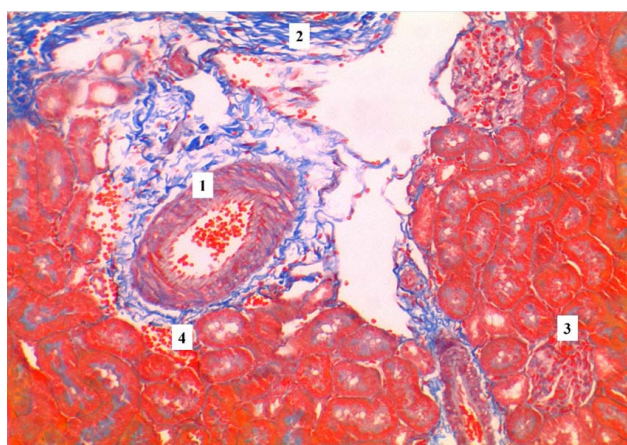


Fig. 4. Morphological changes in rat kidneys under conditions of intoxication with the venom of the viper *Vipera berus nikolskii*: 1 – Renal vessel lumen, 2 – interstitial connective tissue fibres, 3 – renal corpuscle, 4 – haemorrhage zone. Azan staining. $\times 100$.

into a single, structureless, homogeneous mass. Between the basement membrane and the epithelial cell layer, areas of transudate accumulation are noted, which are stained pale blue (Fig. 4).

Adventitial vessel swelling is characteristic. Blue collagen around the arteries appears loose, indicating deep vascular permeability. Accumulations of orange-red masses are observed in the lumens of the vessels and in areas of haemorrhage. In areas of the most massive necrosis, thickening of reticular fibres is noted, which may be the beginning of a rapid reactive organisation of the tissue (Fig. 5).

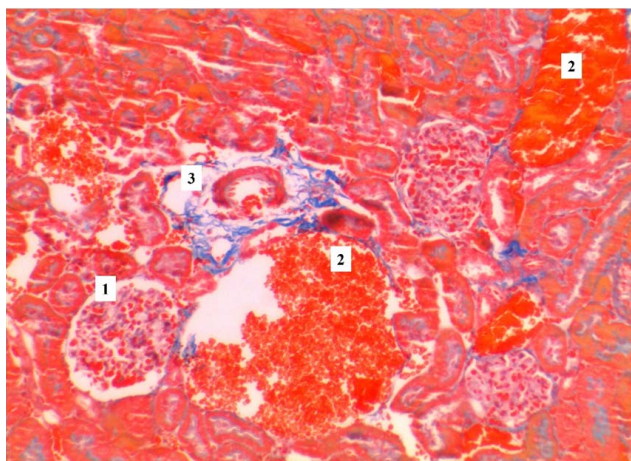


Fig. 5. Microscopic changes in the kidneys of rats under conditions of intoxication with the venom of the viper *Vipera berus nikolskii*: 1 – Renal corpuscle, 2 – foci of haemorrhage, 3 – interstitial connective tissue. Staining with azan. $\times 100$.

Discussion. Experimental studies have shown that components of snake venoms exhibit direct and indirect toxicity to the structural elements of the kidney tissue. Direct effects are associated with the development of glomerulonephritis and mesangiolysis, while indirect effects are due to the production of exogenous cytokines and mediators and to the consequences of their action [18]. Pathological changes in the glomeruli cause proteinuria and can contribute to nephrotoxicity, which was first demonstrated in an animal model after intravenous administration of *Bothrops moojeni* venom to rats. Mesangiolysis, the formation of microaneurysms, are consequences of the high proteolytic (PLA2) activity of this venom [19].

Enzyme toxins in snake and viper venom are key players in damaging target organs, including the kidneys. Thus, matrix metalloproteases cleave extracellular matrix components, disrupt intercellular contacts, and induce apoptosis [20]. P-III type

metalloproteases are involved in platelet aggregation inhibition and activation of blood clotting factors, and they also exhibit a direct nephrotoxic effect [21–24]. PLA2, which is the most numerous group of snake venom enzymes, acting on cell membranes in the victim's body, contributes to their partial or complete lysis, the release of arachidonic acid, which, in turn, activates cyclooxygenase, lipoxygenase, cytochrome P450, and PIK3-kinase [25–27]. The launch of these signalling pathways is accompanied by the production of prostaglandins, thromboxanes, and leukotrienes, the development of inflammation, increased gene expression, vasodilation, increased vascular wall permeability, and chemotaxis. Activation of the complement system, under these conditions, the deposition of C3 and IgM in the mesangium of the renal glomeruli causes the development of acute immune-mediated glomerulonephritis. Often, the histological sign of kidney damage caused by snake and viper bites is the deposition of fibrin in the glomerular capillaries and Bowman's capsule, resulting in a pronounced picture of proliferative glomerulonephritis. PLA2, in addition to the above effects, can stimulate the hypothalamic-pituitary-adrenal axis, leading to the production of ACTH, corticosteroids, vasopressin, and acute-phase proteins [28].

In some clinical cases, acute interstitial nephritis has been reported [29]. The appearance of interstitial inflammation, infiltration by lymphocytes, eosinophils, neutrophils, and accumulation of complement C1q are characteristic features of this pathological condition [30].

Conclusions. Intoxication with the venom of the viper *Vipera berus nikolskii* causes the development of acute necrotic nephrosis, which is characterised by a combination of deep parenchymal dystrophy, destruction of the glomerular apparatus and massive hemorrhagic syndrome with the destruction of the histo-hematological barrier of the kidneys and enzymatic lysis of the basement membranes of the glomerular capillaries and Bowman's capsule. The transition from dystrophy to coagulation necrosis, with massive karyorrhexis, karyolysis, and the formation of structureless cellular detritus, is observed. The vasotoxic effect of the venom manifests as multiple extravasations that tend to merge, forming extensive hemorrhagic foci in the cortical substance, thereby causing critical compression of the interstitium and increased ischemic damage to the parenchyma.

Conflict of interest. The authors declare that they have no conflict of interest.

Sources of financing. No external sources of funding or support were involved. No fees or other compensation were paid.

Authors' contribution. K. M. Ahafonov – literature review, collection of material, analysis of the results obtained, preparation of the text of the article and design of illustrations.

Prospects for further research. Study of histological changes in the kidneys of rats exposed to the venom of another species of viper – *Vipera berus nikolskii* and comparative characterisation of the effects of these venoms.

REFERENCES

- Chaiyabutr N, Chanhom L, Vasaruchapong T, Laoungbua P, Khoo O, Rungsipipat A, Sitprijia V. The pathophysiological effects of Russell's viper (*Daboia siamensis*) venom and its fractions in the isolated perfused rabbit kidney model: A potential role for platelet activating factor. *Toxicon X*. 2020; 7:100046. DOI: 10.1016/j.toxcx.2020.100046.
- Larréché S, Chippaux JP, Chevillard L, Mathé S, Résière D, Siguret V, Mégarbane B. Bleeding and Thrombosis: Insights into Pathophysiology of *Bothrops* Venom-Related Hemostasis Disorders. *Int J Mol Sci*. 2021; 22 (17):9643. DOI: 10.3390/ijms22179643.
- Mora-Obando D, Salazar-Valenzuela D, Pla D, Lomonte B, Guerrero-Vargas JA, Ayerbe S, Calvete JJ. Venom variation in *Bothrops asper* lineages from North-Western South America. *J Proteomics*. 2020; 229:103945. DOI: 10.1016/j.jprot.2020.103945.
- Park EJ, Choi S, Kim HH, Jung YS. Novel Treatment Strategy for Patients with Venom-Induced Consumptive Coagulopathy from a Pit Viper Bite. *Toxins (Basel)*. 2020; 12(5):295. DOI: 10.3390/toxins12050295.
- Adisakwattana P, Chanhom L, Chaiyabutr N, Phuphisut O, Onrapak R, Thawornkuno C. Venom-gland transcriptomics of the Malayan pit viper (*Calloselasma rhodostoma*) for identification, classification, and characterization of venom proteins. *Heliyon*. 2023; 9 (5):e15476. DOI: 10.1016/j.heliyon.2023.e15476.
- AlShammari AK, Abd El-Aziz TM, Al-Sabi A. Snake Venom: A Promising Source of Neurotoxins Targeting Voltage-Gated Potassium Channels. *Toxins (Basel)*. 2023; 16(1):12. DOI: 10.3390/toxins16010012.
- Frangieh J, Rima M, Fajloun Z, Henrion D, Sabatier JM, Legros C, Mattei C. Snake Venom Components: Tools and Cures to Target Cardiovascular Diseases. *Molecules*. 2021; 26(8):2223. DOI: 10.3390/molecules26082223.
- Siigur J, Siigur E. Biochemistry and toxicology of proteins and peptides purified from the venom of *Vipera berus berus*. *Toxicon X*. 2022; 15:100131. DOI: 10.1016/j.toxcx.2022.100131.
- Albert V, Hall MN. mTOR signaling in cellular and organismal energetics. *Curr Opin Cell Biol*. 2015; 33:55-66. DOI: 10.1016/j.ceb.2014.12.001.
- Chun Y, Kim J. AMPK-mTOR Signaling and Cellular Adaptations in Hypoxia. *Int J Mol Sci*. 2021; 22(18):9765. DOI: 10.3390/ijms22189765.
- Fantus D, Rogers NM, Grahame F, Huber TB, Thomson AW. Roles of mTOR complexes in the kidney: implications for renal disease and transplantation. *Nat Rev Nephrol*. 2016; 12(10):587-609. DOI: 10.1038/nrneph.2016.108.
- Toyama EQ, Herzig S, Courchet J, Lewis TL Jr, Losón OC, Hellberg K, Shaw RJ. Metabolism. AMP-activated protein kinase mediates mitochondrial fission in response to energy stress. *Science*. 2016; 351(6270):275-81. DOI: 10.1126/science.aab4138.
- Zhang H, Xu R, Wang Z. Contribution of Oxidative Stress to HIF-1-Mediated Profibrotic Changes during the Kidney Damage. *Oxid Med Cell Longev*. 2021; 6114132. DOI: 10.1155/2021/6114132.
- Palikaras K, Tavernarakis N. Mitochondrial homeostasis: the interplay between mitophagy and mitochondrial biogenesis. *Exp Gerontol*. 2014; 56:182-88. DOI: 10.1016/j.exger.2014.01.021.
- Singh JP, Singh AP, Bhatti R. Explicit role of peroxisome proliferator-activated receptor gamma in gallic acid-mediated protection against ischemia-reperfusion-induced acute kidney injury in rats. *J Surg Res*. 2014; 187(2): 631-39. DOI: 10.1016/j.jss.2013.11.1088.
- Whitaker RM, Corum D, Beeson CC, Schnellmann RG. Mitochondrial Biogenesis as a Pharmacological Target: A New Approach to Acute and Chronic Diseases. *Annu Rev Pharmacol Toxicol*. 2016; 56:229-49. DOI: 10.1146/annurev-pharmtox-010715-103155.
- Zhang J, Pan W, Zhang Y, Tan M, Yin Y, Li Y, Li H. Comprehensive overview of Nrf2-related epigenetic regulations involved in ischemia-reperfusion injury. *Theranostics*. 2022; 12(15):6626-45. DOI: 10.7150/thno.77243.
- Ferreira BA, Deconte SR, de Moura FBR, Tomiosso TC, Clissa PB, Andrade SP, Araújo FA. Inflammation, angiogenesis and fibrogenesis are differentially modulated by distinct domains of the snake venom metalloproteinase jararhagin. *Int J Biol Macromol*. 2018; 119:1179-87. DOI: 10.1016/j.ijbiomac.2018.08.051.
- Albuquerque PL, Jacinto CN, Silva Junior GB, Lima JB, Veras Mdo S, Daher EF. Acute kidney injury caused by *Crotalus* and *Bothrops* snake venom: a review of epidemiology, clinical manifestations and treatment. *Rev Inst Med Trop Sao Paulo*. 2013; 55(5):295-301. DOI: 10.1590/S0036-46652013000500001.
- Gutiérrez JM, Escalante T, Rucavado A, Herrera C, Fox JW. A Comprehensive View of the Structural and Functional Alterations of Extracellular Matrix by Snake Venom Metalloproteinases (SVMPs): Novel Perspectives on the Pathophysiology of Envenoming. *Toxins*. 2016; 8:304. DOI: 10.3390/toxins8100304.
- Bertholim L, Chaves AFA, Oliveira AK, Menezes MC, Asega AF, Tashima AK, Serrano SMT. Systemic Effects of Hemorrhagic Snake Venom Metalloproteinases: Untargeted Peptidomics to Explore the Pathodegradome of Plasma Proteins. *Toxins (Basel)*. 2021; 13(11):764. DOI: 10.3390/toxins13110764.
- Castro AC, Escalante T, Rucavado A, Gutiérrez JM. Basement membrane degradation and inflammation play a role in the pulmonary hemorrhage induced by a P-III snake venom metalloproteinase. *Toxicon*. 2021; 197:12-23. DOI: 10.1016/j.toxicon.2021.04.012.
- Kini RM, Koh CY. Metalloproteinases Affecting Blood Coagulation, Fibrinolysis and Platelet Aggregation from Snake Venoms: Definition and Nomenclature of Interaction Sites. *Toxins (Basel)*. 2016; 8(10):284. DOI: 10.3390/toxins8100284.
- Olaoba OT, Karina Dos Santos P, Selistre-de-Araujo HS, Ferreira de Souza DH. Snake Venom Metalloproteinases (SVMPs): A structure-function update. *Toxicon X*. 2020; 7:100052. DOI: 10.1016/j.toxcx.2020.100052.
- Bickler PE. Amplification of Snake Venom Toxicity by Endogenous Signaling Pathways. *Toxins (Basel)*. 2020; 12(2):68. DOI: 10.3390/toxins12020068.

26. Lazarovici P, Marcinkiewicz C, Lelkes PI. From Snake Venom's Disintegrins and C-Type Lectins to Anti-Platelet Drugs. *Toxins (Basel)*. 2019; 11(5):303. DOI: 10.3390/toxins11050303.
27. Silva A, Johnston C, Kuruppu S, Kneisz D, Maduwage K, Kleifeld O, Isbister GK. Clinical and Pharmacological Investigation of Myotoxicity in Sri Lankan Russell's Viper (*Daboia russelii*) Envenoming. *PLoS Negl Trop Dis*. 2016; 10(12):e0005172. DOI: 10.1371/journal.pntd.0005172.
28. Cedro RCA, Menaldo DL, Costa TR, Zoccal KF, Sartim MA, Santos-Filho NA, Sampaio SV. Cytotoxic and inflammatory potential of a phospholipase A₂ from *Bothrops jararaca* snake venom. *J Venom Anim Toxins Incl Trop Dis*. 2018;24:33. DOI: 10.1186/s40409-018-0170-y.
29. Ratnayake I, Mohamed F, Buckley NA, Gawarammana IB, Dissanayake DM, Chathuranga U, Isbister GK. Early identification of acute kidney injury in Russell's viper (*Daboia russelii*) envenoming using renal biomarkers. *PLoS Negl Trop Dis*. 2019; 13(7):e0007486. DOI: 10.1371/journal.pntd.0007486.
30. Marinho AD, Morais IC, Lima DB, Jorge AR, Jorge RJ, Menezes RR, Monteiro HS. Bothropoides pauloensis venom effects on isolated perfused kidney and cultured renal tubular epithelial cells. *Toxicol*. 2015; 108:126-33. DOI: 10.1016/j.toxicol.2015.09.031.

Received for editorial office on / Надійшла до редакції: 09.01.2026
Accepted after review on / Прийнята після рецензування: 03.02.2026
Submitted for printing on / Подана до друку: 19.02.2026

E-mail address for correspondence: kostya.agafonov2013@gmail.com

K. M. АГАФОНОВ

Вінницький національний медичний університет імені М. І. Пирогова, Вінниця, Україна

ЗМІНИ ГІСТОАРХІТЕКТОНІКИ НИРОК ЕКСПЕРИМЕНТАЛЬНИХ ЩУРІВ ЗА УМОВ ВВЕДЕННЯ ОТРУТИ ГАДЮК *Vipera berus nikolskii*

Мета роботи: дослідити морфологічні зміни нирок експериментальних щурів за умов введення отрути гадюки *Vipera berus nikolskii*.

Матеріали і методи. Експериментальні дослідження проводили на білих нелінійних щурах-самцях. Тварин поділили на дві групи: контрольну та експериментальну – по 10 особин у кожній. Експериментальні щури отримували внутрішньочеревну ін'єкцію напівлетальної дози (LD₅₀) отрути *Vipera berus nikolskii* у фізіологічному розчині в концентрації 0,972 мг·г⁻¹. Отруту гадюки (*Vipera berus nikolskii*) отримали в Харківському національному університеті імені В. Н. Каразіна. Ліофілізовану нативну отруту зберігали при температурі мінус 20 °С та розчиняли у фізіологічному розчині безпосередньо перед експериментом. Контрольній групі вводили лише фізіологічний розчин. Через 24 год щурам було проведено евтаназію шляхом декапітації після анестезії. Гістологічні препарати досліджували під світловим мікроскопом «SEO SCAN» та фіксували за допомогою CCD-камери «Vision», оснащеної системою виведення зображення.

Результати. Гістологічний аналіз впливу отрути гадюки *Vipera berus nikolskii* на нирки продемонстрував наявність глибоких деструктивних змін органа тварин. Це зумовлено потужним поєднанням фосфоліпаз A₂ та металопротеїназ отрути, що призводить до системного цитолізу та вазопатії. Спостерігаються тотальна дезорганізація впорядкованості ниркових тілець, явища гломерулярного некробіозу, десквамція зовнішнього листка капсули Шумлянського – Боумена. Відзначається виражена лімфогістіоплазмоцитарна інфільтрація паренхіми органа. Морфологічні зміни в епітелії каналців нефронів нирки за даних умов мають характер гострого некротичного нефрозу.

Висновки. Інтоксикація отрутою гадюк *Vipera berus nikolskii* зумовлює розвиток гострого некротичного нефрозу. Простежується перехід дистрофії у стадію коагуляційного некрозу з масовим каріорексисом, каріолізисом та формуванням безструктурного клітинного детриту. Відзначаються множинні екстравазати, обширні геморагічні вогнища у кірковій речовині.

Ключові слова: отрута; змії; нирки; запалення; некроз; морфологія; щури.

Information about author

Агафонов К. М. – Postgraduate PhD Student of the Department of Pathological Physiology, National Pirogov Memorial Medical University, Vinnytsya, Ukraine, e-mail: kostya.agafonov2013@gmail.com.

Відомості про автора

Агафонов К. М. – аспірант кафедри патологічної фізіології Вінницького національного медичного університету імені М. І. Пирогова, Вінниця, Україна, e-mail: kostya.agafonov2013@gmail.com.