

P.A. Dyachenko

«IDIOPATHIC» MENINGOENCEPHALITIS IN YOUNG ADULT INFECTED WITH HERPES SIMPLEX VIRUS

L. Hromashevskiy Institute of Epidemiology and Infection Diseases of the National Academy
of Medical Sciences of Ukraine, Kyiv)

Background. Central nervous system tuberculosis is one of the most severe forms of extra-pulmonary tuberculosis. Tuberculous meningoencephalitis (TBM) is highly prevalent globally in resource-limited countries and in patients with immunosuppression. We present here a case of meningoencephalitis with proved acute Herpes simplex virus infection. However, our patient responded to antituberculosis therapy. This raises the possibility that some cases of "idiopathic" (cryptogenic) meningoencephalitis may represent occult tuberculosis disease.

Result. A 22-year-old woman was admitted to our hospital because of fever, headache and hallucinations. Neck stiffness and other meningeal symptoms were present. CSF examination showed lymphocyte-dominant pleocytosis and a decreased level of glucose. Both Herpes simplex virus type 1 (HSV-1) DNA and IgG antibodies to the virus were found in the CSF sample. Although antibiotics and acyclovir were administered, fever, disturbance of consciousness, hallucinations and meningeal signs intensified. A second CSF sample obtained a week after the collection of the first one contained higher level of cytosis and so called "spider-web" cloth (SWC). As a result, the diagnosis was revised: tuberculosis was regarded as the most likely cause of the disease. The patient started receiving antituberculous treatment. Soon after the medications were changed, the meningoencephalitis started to subside and was finally cured. Judging from the clinical features, the CSF and MRI findings, the effectiveness of antituberculous drugs, the final diagnosis was made as tuberculous meningoencephalitis. From all these things, we conclude when even antibodies for Herpes viruses and viral DNA are present in the CSF of the patient with sterile meningoencephalitis the possibility of latent involvement in the process of Koch bacteria (KB) should be kept in mind.

Conclusion. The patient's symptoms and signs began to resolve with antituberculous therapy. Resolution of the lesions was confirmed by magnetic resonance imaging. We conclude that this case represented occult tuberculous disease. An empiric trial of antituberculous therapy may be used in other cases of apparently idiopathic meningoencephalitis.

Key words: meningitis, encephalitis, tuberculosis, herpesvirus.

Tuberculosis is one of the most urgent medical and social problems due to the severe clinical course, significant dissemination among the population, the tendency of an increase in the number of patients, their high disability and mortality, limited diagnostic capacity and antituberculous therapy and the multiple drug resistance of its pathogen. Tuberculous meningoencephalitis, which accounts for approximately 6 % of all cases of extra-pulmonary tuberculosis (TB), is one of the most serious clinical forms of TB, with a high mortality rate and disabling neurological sequelae [1,2]. Relatively rare in Europe TBM often has atypical onset and evolution, highly heterogeneous and unspecific clinical symptoms that result in a delayed diagnosis. Prognosis therefore is poor, despite adequate treatment. Often tuberculosis and TBM are observed in people with immunosuppression and, above all, HIV-infected. Beside HIV, other pathogens can suppress immunity and accompany TB. Below we present the case of TBM in a young adult woman co-infected with HSV-1/2.

Case Presentation

Patient information

A 22-year-old woman living in an urban area in Ukraine was presented to The Center of Infectious Disorders of the Nervous System (CIDNS, Kyiv, Ukraine) in March 2017 with dizziness, 2-week history of fever, severe frontal headache, a sense of "heaviness" in the head, weakness, memory impairment, cervical and lumbar pain and vomiting during the last 3 days. The patient was in good health until a month before admission to our clinic. After severe stress specific symptoms developed. She was admitted to the local hospital, where she was treated with anti-inflammatory and neuroprotective drugs for 2 weeks. Lumbar puncture (LP) was not performed. Since her fever and intoxication symptoms worsened she was presented to CIDNS for further follow-up and treatment.

Personal history

The patient denied TB and previous disorders of the CNS. She had no history of immunosuppression.

Clinical findings

On admission, general condition of the patient was severe. Clinical manifestations observed included: fever, headache, weakness. She was weakly oriented, emotionally labile, and answered the questions adequately. She also experienced visual and auditory hallucinations (critical). The patient presented cranial nerve dysfunctions (rightward-ptosis, eyelids tremor, diplopia), left-beating nystagmus, smoothed leftward-nasolabial fold, mitigated deep tendon reflexes in her lower extremities, reduced muscular strength on the leftward, tremor of the hands during complicated Barre-test, and dysmetria, which was observed on the finger-to-nose test. Lasseg, Nery, Gordon, Stryumpel, Sharapov-Raskolnikov, Chaddock, Pussep, Babinsky signs were positive on one or both sides in addition to a stiff neck and meningeal symptoms (Kernig/Brudzinsky).

Diagnostic focus and assessment

A blood test revealed small neutrophilic leukocytosis. Cerebrospinal fluid (CSF) analysis showed (Table 1) significant mononuclear pleocytosis of 247 cells/mm³ (mononuclear cells, 88%; PMNC, 12%); glycorrhachia, 1.7 mmol/L; proteinorachia, 0.99 g/L; and CSF/blood glucose ratio, 0.35. PCR of the CSF was reported to be positive for HSV-1 DNA (5734 genome copies per ml) and negative for the other pathogens usually tested (herpesviruses type 2–8, enteroviruses type 70/71, adenoviruses, *Toxoplasma gondii*). Intrathecal synthesis of the G class antibodies against HSV-1/2 were also revealed. No DNA nor antibodies to viral and bacterial proteins were detected in the blood. Microscopic examination for acid-fast bacilli of CSF revealed negative result. CSF culture was sterile.

MR brain imaging (Fig.1) in T2W, FLAIR, and T1W mode showed a mild expansion of the perivascular space in the projection of basal nuclei of both hemispheres. The regions of hyperintensive MR signal on T2 mode were located in various parts of the right hemisphere.

On the basis of the received data, a *suspected* (preliminary) diagnosis was made: herpes simplex virus-associated meningoencephalitis. Patient was empirically treated with cefoperazone/sulbactam, 2 g, intravenous twice daily; dexamethasone, 12 mg per day; acyclovir, 1 g intravenous twice daily, two times per day; ademetonine, 400 mg daily. As a result of the treatment, the patient's state improved somewhat (the volume of hallucinations and cephalgic syndrome decreased), however, second CSF sample obtained 7 days after the collection of the first one showed higher level of cytotosis, 317 (85% lymphocyte, 15% PMNC), and lower level of glucose (0.6 mmol/L). Besides, a «spider-web» cloth (SWC, specific fibrin film) was firstly detected. Radiological examination of the lungs (CT) revealed no changes in the parenchyma. In accordance with the new data treatment was completed with isoniazid, 10 mg/kg per day, intravenously by drip; ethambutol, 400 mg two times per day; and rifampicin, 300 mg two times per day. A control examination after 7 days showed that the

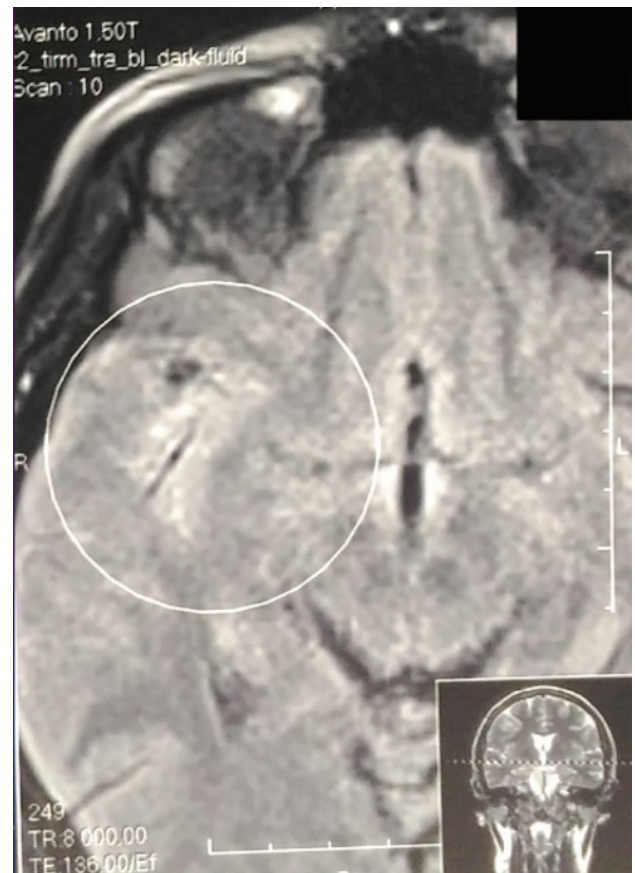


Figure 1. T2 weighted images of MRI brain showing areas of mild increased signal in right parietal lobe (made soon after admission).

cytotosis began to decrease (189 WCC/ml), and the glucose level increased (1.2 mmol/L) with simultaneous slight regression of neurological signs. *M. tuberculosis* DNA was also found in the CSF sample (tbl.1). It allowed the suspected diagnosis to be changed on tuberculous meningoencephalitis. As a result, the treatment also was corrected: cefoperazone/sulbactam, and acyclovir were stopped, and streptomycin, 1.0 g two times per day intramuscular, was added instead. During the next 5 weeks, the complete regression of neurological symptoms (except for finger-to-nose test, which was performed with intent) was observed. Patient was discharged for outpatient treatment 05/24/2017 with a recommendation for control survey after six months.

On admission 09/12/2017, there was no complaints. Neurologically, a slight vestibulo-ataxic syndrome was observed. A control CSF sample contained 15 cells/mm³, 0.66 g/L of protein, 2.7 mmol/L of glucose, IgG to HSV-1/2, and SWC. No DNA was detected in the CSF. MRI brain contained no pathologic foci (fig. 2). The patient was recommended to continue anti-TB treatment for at least a year with checkup.

Results of the CSF testing

CSF	WCC/ ml	Lym/ PMNC, %	Protein, g/L	Glucose, mmol/L	Anti bodies	PCR	«Spider- web» cloth
03/28	247	88/12	0.99	1.7	HSV-1/2	HSV-1	–
04/05	317	85/15	0.66	0.6	«	«	+
04/12	189	85/15	0.99	1.2	«	KB	+
04/21	151	71/29	0.99	1.4	«	«	+
05/08	51	93/7	0.99	2.6	«	«	–
05/22	25	90/10	0.66	2.5	«	«	–
09/13	15	90/10	0.66	2.7	«	–	+

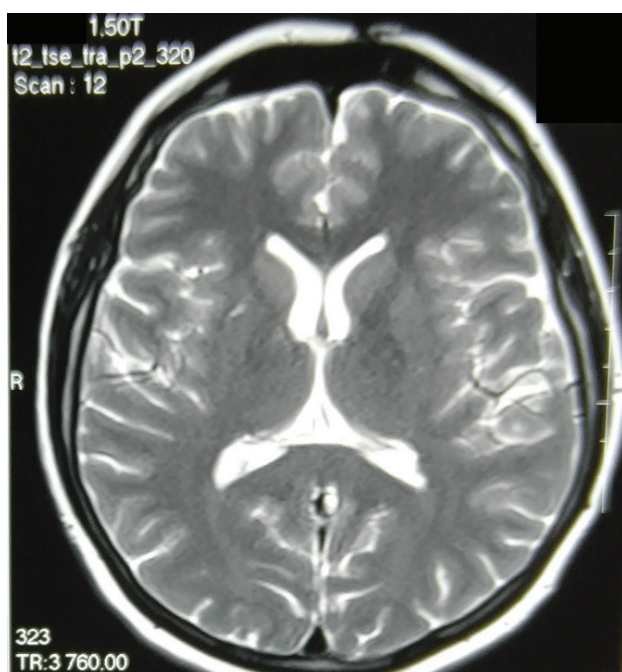


Figure 2. Control MR brain scan after 5 months of antituberculous therapy shown no pathologic changes.

Discussion

Tuberculous meningoencephalitis is a rare but extremely dangerous form of tuberculosis, characterized with high mortality. Only the early treatment allows patient's recovery. The case presented above highlights the challenges in diagnosis of TBM. It is of interest primarily because the treatment was an important imperative of the correct diagnosis. Indeed, initially we classified the case as HSV-1-associated meningoencephalitis. This conclusion was absolutely legitimate because it was based on rigorous, formal criteria: the presence in the sterile CSF of HSV-1 DNA and antibodies to the virus. Moreover, the following two weeks' therapy with acyclovir

results in complete virology response but not neurological recovery. On the contrary, the patient's state worsened. So, we were forced to revise the treatment strategy: acyclovir was canceled and set of anti-tuberculous medications was introduced. Prerequisites for that were high cytosis and the appearance of SWC in the CSF. Although both these signs are not specific and observed in many diseases, an empirical treatment soon led to positive dynamic in patient's state. We think that the reactivation of persistent HSV-infection, accompanied by the appearance of HSV-1 DNA and antibodies to the virus in CSF, was triggered by the underlying disease. However, relapse of the HSV-infection had no effect on the pathological process in brain.

It is known, that laboratory diagnosis of TBM based on the results of routine CSF analysis and imaging data is often inadequate in making a correct diagnosis or even leads to a miss diagnosis. Availability of new diagnostic tools does not always help to solve the problem. In addition, the diagnosis should be quick, as it is vital [3]. Ziehl-Neelsen smear is the most rapid detection method with low sensitivity, BK propagation on the Lowenstein-Jensen medium is very slow making it impractical for prompt diagnosis [4]. PCR-based methods are the best for rapid and definitive diagnosis of CNS tuberculosis [5-7]. We used the GeneXpert MTB/RIF test. Sensitivity of Xpert is 59.3% (108/182) [8] that very similar to other systems [9,10]. In the case presented here, the repeated conventional (microscopy, bacteriology) and modern (PCR) tests for tuberculosis revealed firstly to be negative. So, the diagnosis *ex juvantibus* was the only choice.

Conclusion

In our case report, the treatment allowed us to establish the correct diagnosis; fortunately, we could perform the procedure before the patient developed a critical status. The published evidence and presented here our clinical experience suggest the importance and urgent need to develop new specific and high sensitive methods to further improve the diagnosis of TBM to reduce mortality.

Literature

1. Diagnosis of adult tuberculous meningitis by use of clinical and laboratory features / G.E. Thwaites, T.T. Chau, K. Stepniewska [et al.] // *Lancet*. – 2002. – Vol. 360. – P. 1287–1292.
2. Dexamethasone for the treatment of tuberculous meningitis in adolescents and adults / G. E. Thwaites, D. B. Nguyen, H. D. Nguyen [et al.] // *New Engl. J. Med.* – 2004. – Vol. 351. – P. 1741–1751.
3. Diagnosing tuberculous meningitis – have we made any progress? / J. Ho, B. J. Marais, G. L. Gilbert, A. P. Ralph // *Trop. Med. Intern. Health.* – 2013. – Vol. 18, N 6. – P. 783–793.
4. Tuberculous meningitis / D. H. Kennedy, R. J. Fallon // *JAMA*. – Vol. 241. – P. 264–268.
5. Rapid diagnosis of tuberculous meningitis by polymerase chain reaction assay of cerebrospinal fluid / J. J. Lin, H. J. Harn, Y. D. Hsu [et al.] // *J. Neurology*. – 1995. – Vol. 242. – P. 147–152.
6. Use of the Roche AMPLICOR Mycobacterium tuberculosis PCR in early diagnosis of tuberculous meningitis / A. Bonington, J. I. Strang, P. E. Klapper [et al.] // *J. Clin. Microbiol.* – 1998. – Vol. 36. – P. 1251–1254.
7. The potential contribution of the polymerase chain reaction to the diagnosis of tuberculous meningitis / L. N. Nguyen, L. F. Kox, D. P. Lihn [et al.] // *Arch. Neurology*. – 1996. – Vol. 53. – P. 771–776.
8. Evaluation of GeneXpert MTB/RIF for diagnosis of tuberculous meningitis / N. T. Nhu, D. Heemskerck, D. A. Thu do [et al.] // *J. Clin. Microbiol.* – 2014. – Vol. 52, N 1. – P. 226–233. doi: 10.1128/JCM.01834–13. PMID: 24197880.
9. Clinical evaluation of the gen-probe amplified direct test for the detection of mycobacterium tuberculosis complex organisms in cerebrospinal fluid / A. M. Lang, J. Feris-Inglesias, C. Pena [et al.] // *J. Clin. Microbiol.* – 1998. – Vol. 36. – P. 2191–2194.
10. Early detection of central nervous system tuberculosis with the gen-probe nucleic acid amplification assay: utility in an inner city hospital / C. A. Baker, C. P. Cartwright, D. N. Williams [et al.] // *Clin. Infect. Dis.* – 2002. – Vol. 35. – P. 339–342.

References

1. Thwaites, G.E., Chau, T.T., Stepniewska, K., Phu, N.H., Chuong, L.V., Sinh, D.X. ... Farrar J.J. (2002). Diagnosis of adult tuberculous meningitis by use of clinical and laboratory features. *Lancet*, 360, 1287-1292.
2. Thwaites, G.E., Nguyen, D.B., Nguyen, H.D., Hoang, T.Q., Do, T.T., Nguyen, T.C. ... Farrar, J.J. (2004). Dexamethasone for the treatment of tuberculous meningitis in adolescents and adults. *New Engl. J. Med.*, 351, 1741-1751.
3. Ho, J., Marais, B.J., Gilbert, G.L. & Ralph, A.P. (2013). Diagnosing tuberculous meningitis – have we made any progress?. *Trop. Med. Intern. Health*, 18(6), 783-793.
4. Kennedy, D.H., Fallon, R.J. (1979). Tuberculous meningitis. *JAMA*, 241, 264-268.
5. Lin, J.J., Harn, H.J., Hsu, Y.D., Tsao, W.L., Lee, H.S. & Lee, W.H. (1995). Rapid diagnosis of tuberculous meningitis by polymerase chain reaction assay of cerebrospinal fluid. *J. Neurology*, 242, 147-152.
6. Bonington, A., Strang, J.I., Klapper, P.E., Hood, S.V., Rubombora, W., Penny, M. ... Wilkins, E.G. (1998). Use of the Roche AMPLICOR *Mycobacterium tuberculosis* PCR in early diagnosis of tuberculous meningitis. *J. Clin. Microbiol.*, 36, 1251-1254.
7. Nguyen, L.N., Kox, L.F., Lihn, D.P., Sjoukje, K. & Kolk, A.H. (1996). The potential contribution of the polymerase chain reaction to the diagnosis of tuberculous meningitis. *Arch. Neurology*, 53, 771-776.
8. Nhu, N.T., Heemskerck, D., Thu do, D.A., Chau, T.T., Mai, N.T., Nghia, H.D. ... Caws, M. (2014). Evaluation of GeneXpert MTB/RIF for diagnosis of tuberculous meningitis. *J. Clin. Microbiol.*, 52(1), 226-233. doi: 10.1128/JCM.01834-13. PMID: 24197880.
9. Lang, A.M., Feris-Inglesias, J., Pena, C., Sanchez, J.F., Stockman, L., Rys, P. ... Cockerill, F.R. (1998). Clinical evaluation of the gen-probe amplified direct test for the detection of mycobacterium tuberculosis complex organisms in cerebrospinal fluid. *J. Clin. Microbiol.*, 36, 2191-2194.
10. Baker, C.A., Cartwright, C.P., Williams, D.N., Nelson, S.M. & Peterson, Ph.K. (2002). Early detection of central nervous system tuberculosis with the gen-probe nucleic acid amplification assay: utility in an inner city hospital. *Clin. Infect. Dis.*, 35, 339-342.

«ІДІОПАТИЧНИЙ» МЕНІНГОЕНЦЕФАЛІТ У МОЛОДОЇ ДОРОСЛОЇ ЛЮДИНИ, ІНФІКОВАНОЇ ВІРУСОМ ПРОСТОГО ГЕРПЕСУ

П.А. Дьяченко

ДУ «Інститут епідеміології та інфекційних хвороб ім. Л.В. Громашевського НАМН України»

РЕЗЮМЕ. Туберкульоз центральної нервової системи є однією з найбільш тяжких форм позалегенного туберкульозу. Туберкульозний менінгоенцефаліт (ТБМ) надзвичайно поширений у глобальному масштабі, особливо у країнах з обмеженими ресурсами та у пацієнтів з імунодепресією. Ми представляємо приклад менінгоенцефаліту, який супроводжувався інфекцією вірусом простого герпесу. Проте наш пацієнт відреагував на протитуберкульозну терапію. Це свідчить про можливість того, що деякі випадки «ідіопатичного» (криптогенного) менінгоенцефаліту можуть бути проявами прихованого туберкульозу.

Результати. 22-річна жінка була госпіталізована через лихоманку, біль голови та галюцинації. При огляді була виявлена ригідність м'язів шиї та інші менінгеальні симптоми. Аналіз спинномозкової рідини (СМР) виявив плейоцитоз з домінуванням лімфоцитів і зниження рівня глюкози. Були також знайдені антитіла класу G до ВПГ та ДНК цього вірусу. Втім, попри призначення антибіотиків та ацикловіру, стан пацієнтки погіршився, а клінічні ознаки захворювання підсилилися. Другий зразок СМР, отриманий через тиждень після забору пер-

шого, мав вищий рівень цитозу та містив так звану «павутинку» (характерний згусток фібрину). Це примусило переглянути діагноз: туберкульоз став вважатися найбільш ймовірною причиною захворювання. Пацієнтці було призначено протитуберкульозне лікування. Незабаром стан хворої почав покращуватися, а симптоми хвороби значно зменшилися.

Висновок. Навіть за наявності антитіл до вірусів герпесу та вірусної ДНК у СМР пацієнтів зі стерильним менінгоенцефалітом слід пам'ятати про можливість прихованого втручання в процес бактерій Коха.

Ключові слова: менінгіт, енцефаліт, туберкульоз, герпесвірус.

Відомості про автора:

Дьяченко Павло Анатолійович – к. мед. н., старший науковий співробітник відділу нейроінфекцій ДУ «Інститут епідеміології та інфекційних хвороб ім. Л.В. Громашевського НАМН України», e-mail: padyac@gmail.com

Information about author:

Diachenko Pavlo – Candidate of Medicine, Senior Researcher of the Department of Neuroinfections of L. Hromashevskyyi Institute of Epidemiology and Infection Diseases of the National Academy of Medical Sciences of Ukraine

Конфлікту інтересів немає.

The author has no conflicts of interest to declare.

Отримано 16.02.2018 р.