



Missed gall bladder malignancy: A result of ignoring predisposing factors

Sanya Bhushan

Bachelor of Medicine, Bachelor of Surgery, Resident
FH Medical College
283201, NH-2 Railway over Bridge, Agra, India
<https://orcid.org/0009-0008-1247-1818>

Abhinav Mittal*

Bachelor of Medicine, Bachelor of Surgery, Associate Professor
FH Medical College
283201, NH-2 Railway over Bridge, Agra, India
<https://orcid.org/0009-0003-0979-4484>

Mirza Faraz Beg

Bachelor of Medicine, Bachelor of Surgery, Assistant Professor
FH Medical College
283201, NH-2 Railway over Bridge, Agra, India
<https://orcid.org/0009-0005-2314-2102>

Aakansha Agarwal

Bachelor of Medicine, Bachelor of Surgery, Resident
FH Medical College
283201, NH-2 Railway over Bridge, Agra, India
<https://orcid.org/0009-0007-8839-8840>

Abstract. The underestimation of the prevalence of gallbladder carcinoma, which constitutes a predominant form of malignant neoplasm affecting the biliary tract, poses a significant threat due to its asymptomatic progression. Therefore, this study aimed to analyse the clinical, imaging, and intraoperative outcomes in cases of gallbladder carcinoma. This retrospective investigation was conducted from September 2022 to March 2023 at the Department of General Surgery of FH Medical College. A total of 153 patients deemed suitable for surgery participated in this study and underwent the relevant procedures. Various diagnostic and laboratory tests were administered to the patients, including blood analysis, random blood sugar determination, viral markers, chest X-ray, renal and hepatic functional tests, and comprehensive abdominal ultrasound. Gallbladder specimens were subjected to histopathological examination, and the results were documented and analysed. In histopathological reports, signs of precancerous lesions were noted in 30 out of 153 patients who underwent surgical treatment. The frequency of the disease was higher among women. Among these 30 patients, 22 had ultrasound-diagnosed gallstone disease with acute or chronic cholecystitis, while 8 patients had gallstone disease without gallbladder wall thickening. Additionally, 9 of these patients exhibited focal/irregular/thickening of the wall ≥ 10 mm. Overall, 16 patients showed elevated liver function, and 4 had an increased glucose level among those with histopathological evidence of precancerous lesions. This study underscores the elusive nature of gallbladder cancer, emphasizing the necessity for a comprehensive assessment, meticulous preoperative evaluation, and a multidisciplinary approach to facilitate early detection and treatment.

Keywords: laparoscopic cholecystectomy; gallbladder carcinoma; histopathological examination; computed tomography scan

Suggest Citation:

Bhushan S, Mittal A, Beg MF, Agarwal A. Missed gall bladder malignancy: A result of ignoring predisposing factors. *Int J Med Med Res.* 2023;9(2):6–14. DOI: 10.61751/ijmmr/2.2023.06

*Corresponding author



Introduction

Gallbladder malignancies, although relatively rare, represent a significant subset of biliary tract cancers, with a global incidence ranging from 0.3% to 1.5% [1]. In India, as reported by V. Jha *et al.* [2], the incidence varies from 0.8% to 1%, with central regions reporting higher rates than the southern part. Gallstones increase the risk of gallbladder cancer (GBC) four to sevenfold, accounting for 70%-80% of cases. GBC and dysplastic tumours may resemble benign illnesses, making diagnosis difficult. 0.2%-3.3% of cases are identified incidentally, either intraoperatively or histopathologically [3, 4]. Carcinoma of the gallbladder (CaGB) accounts for roughly two-thirds of all biliary tract malignancies, making it the most prevalent subtype. Due to its anatomical location and insidious, non-specific symptoms, CaGB is frequently diagnosed at an advanced stage, affording only about 25% of patients the opportunity for surgical intervention. Furthermore, CaGB exhibits a high recurrence rate of approximately 60%-70% post-surgery, resulting in an unsatisfactory prognosis, with a 5-year survival rate reaching from 5% to 15% [5, 6]. The onset of GBC has been associated with a range of genetic and environmental factors, including chronic gallbladder infection, exposure to toxins and heavy metals, as well as dietary elements, all contributing to the development of GBC. CaGB is linked to the female gender and certain geographical areas in developing countries. It is influenced by factors like female hormones, cholesterol metabolism, and Salmonella infections. There are various factors that can contribute to the development of gallstones. These include conditions like porcelain gallbladder and Mirizzi's syndrome, as well as issues like pancreatic bile reflux. Additionally, a family history of gallstones, smoking, chemical exposure, and living in the Gangetic belt can also increase the risk. Elevated levels of secondary bile acids and a diet high in fried foods prepared with recycled oil are also associated with a higher likelihood of developing gallstones [7, 8]. CaGB is challenging to diagnose preoperatively due to vague symptoms and the inaccessibility of the gallbladder for biopsy. It often mimics benign gallbladder diseases and is typically identified late in its progression. Early diagnosis with surgical intervention is not always feasible, as most patients present at an advanced, inoperable stage. Therefore, as J.C. Roa *et al.* [6] emphasize, considering adjuvant therapy is crucial. The prognosis for CaGB patients largely hinges on disease severity and histological subtype. Various tissue diagnostic techniques, such as bile cytology, needle aspiration, and gallbladder biopsy, substantiate clinical and radiological diagnoses [9].

According to U. Dutta *et al.* [8], India carries a significant burden of gallbladder carcinoma, accounting for approximately 10% of the global CaGB cases. Considering potential underdiagnoses in these statistics, it is crucial to ensure that individuals with this condition receive proper treatment for an improved quality of life. Additionally, S. Vuthaluru *et al.* [10] study indicates a projected significant increase in the global prevalence of GBC over the next two decades, marked by regional and demographic

variations, further underscoring the importance of addressing this issue for enhanced patient outcomes.

The rationale for conducting this study lies in the critical need to address the challenges associated with missed gallbladder malignancies. GBC is often diagnosed late, resulting in poor prognoses. Therefore, this study sought to investigate clinical, imaging, and intraoperative observations in patients diagnosed with CaGB, to elucidate the factors contributing to missed gallbladder malignancy and underscore the significance of recognizing predisposing factors for early detection and intervention.

Materials and Methods

This retrospective study was conducted within the Department of General Surgery at FH Medical College, spanning from September 2022 to March 2023. Over a period of seven months, a total of 166 patients were admitted for pre-operative assessment and anaesthesia check-up, specifically for cholecystectomy, a surgical procedure to remove the gallbladder. As part of the assessment process, these patients underwent a comprehensive set of medical evaluations including complete blood count (CBC), random blood sugar (RBS) measurement, screening for viral markers, chest X-ray, renal function tests, liver function tests, and ultrasound of the whole abdomen. In cases where there were suspicions of specific gallbladder conditions, magnetic resonance cholangiopancreatography (MRCP) was also conducted. Among the initial group, 153 patients who were deemed fit for surgery due to the presence of large gallstones or polyps underwent the cholecystectomy procedure and were enrolled in the study.

It is noteworthy that individuals with a medical history of conditions such as diabetes, hypertension, immune compromise, or those who expressed unwillingness to participate were excluded from the study. Furthermore, the excised gallbladders of all patients included in the study were subjected to histopathological examination (HPE), allowing for a more comprehensive assessment of the gallbladder conditions, and contributing to the overall findings of the study. For this, the extracted tissue is fixed in a preservation solution like formalin to maintain its structural integrity before embarking on the intricate journey of processing. This involves dehydrating the tissue with alcohol and clearing it using substances like xylene, rendering it receptive to embedding within paraffin wax blocks. These blocks serve as the foundation for microtome sectioning, a delicate process where the tissue is meticulously sliced into exceedingly thin sections. These thin sections are then mounted onto glass slides, a crucial preparatory step preceding the application of specialised staining procedures. Staining the tissue sections with dyes like haematoxylin and eosin facilitates the visualization of cellular structures under the microscope, imparting distinct colours to nuclei, cytoplasm, and various tissue components. The final phase involves microscopic examination by skilled professionals, wherein the stained slides are meticulously scrutinised to identify any aberrations in cellular architecture, indicative of gallbladder carcinoma. The

data were recorded in Microsoft Excel 2019 and presented as mean ± standard deviation for continuous variables and frequency for categorical variables. The authors have collected and preserved written participant consent per international or university standards. The study also adhered to the ethical norms of the Declaration of Helsinki [11].

Results

Of the 153 patients who were operated on, 30 had reports suggestive of pre-malignant lesions in their histopathological reports. Most of the patients were aged >50 years (80.00%), and belonged to the lower middle class (40.00%). Female preponderance was noted among the patients (Table 1).

Table 1. Demographic parameters of enrolled patients identified with CaGB

Demographic parameters	No. of patients [n = 30]	Percentage (%)
Age group	≤ 50 years	6
	> 50 years	24
Gender	Male	12
	Female	18
Body mass index	< 18.5	6
	18.5-24.9	2
	25-29.9	3
	30-34.9	6
	35-39.9	8
	≥ 40	5
Socio-economic status	Upper class	3
	Upper middle class	2
	Lower middle class	12
	Upper lower class	10
	Lower class	3
Duration of symptoms (weeks)	0-10	2
	11-20	6
	21-30	7
	31-40	5
	> 40	10

Source: compiled by the authors

Abdominal pain was the predominant complaint, reported by a significant majority of patients, with 26 individuals (86.67%) expressing this symptom. Weight loss was the second most common complaint, though notably less frequent, reported by 8 patients (26.67%). A smaller percentage of patients complained of jaundice (6.67%) and

vomiting (6.67%), indicating less frequent but notable clinical presentations. This data underscores the prevalence of abdominal pain as a primary symptom in gallbladder conditions and highlights the need for vigilant assessment and consideration of less common symptoms for early detection and diagnosis (Fig. 1).

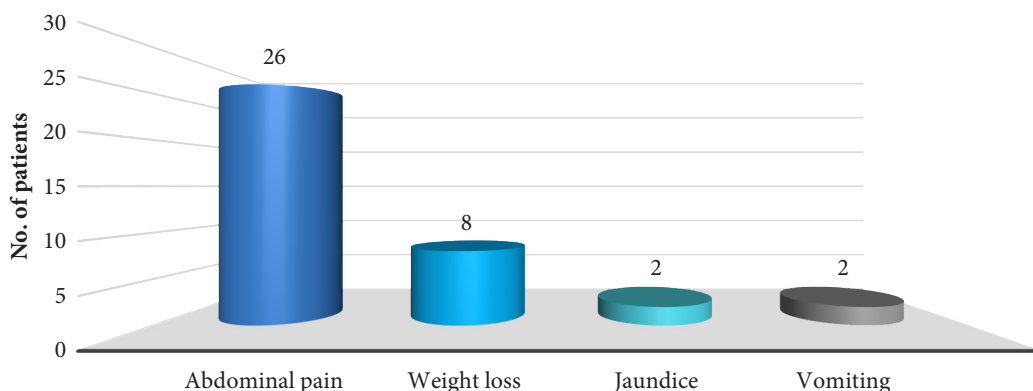


Figure 1. Chief complaints of patients identified with CaGB

Source: compiled by the authors

When examining the duration of symptoms, it was notable that 10 patients had symptoms lasting longer than 40 weeks, while 6 patients reported symptoms lasting between 11 and 20 weeks. After observing weight loss as one of the presenting complaints, it was recorded that most patients (26.67%) had a body mass index (BMI) of 35-39.9 kg/m²

(Table 1). Data pertaining to the history of smoking reveals that among male patients, 6 individuals (20.00%) reported a history of smoking, while 3 (10.00%) did not have a smoking history. For female patients, 2 individuals (6.67%) indicated a history of smoking, while the majority, 19 patients (63.33%), reported no history of smoking (Fig. 2).

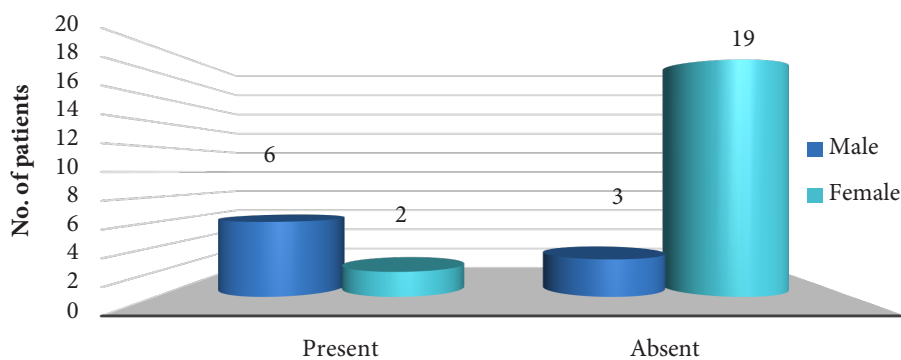


Figure 2. History of smoking in patients identified with CaGB

Source: compiled by the authors

According to the HPE, most of the females had cholelithiasis with intestinal metaplasia (n = 10), while most of the males had cholelithiasis with foci of intestinal metaplasia (n = 6) (Table 2). Another histopathological finding was suggestive of chronic cholecystitis with cholelithiasis, acute on chronic cholecystitis with cholelithiasis and cholelithiasis with xanthochromatous.

The preoperative ultrasonography (USG) showed no evidence or suspicion of malignancy, revealing stones (40.00%) in most patients. Of these 30 CaGB patients, 15 patients had USG findings of chronic cholecystitis, whereas the rest of them had polyploid mass (26.67%), difficult cholecystectomy (13.33%) and thickened wall (10.00%) of ≥ 10 mm (Table 2).

Table 2. Findings of patients identified with CaGB

	Findings	No. of patients [n = 30]	Percentage (%)
USG features	Single stone	12	40.00
	Adenomyomatosis	8	26.67
	Wall thickening, stones	4	13.33
	Multiple stones	3	10.00
	Wall thickening, single-stone	3	10.00
HPE	Cholelithiasis with intestinal metaplasia	Male/female ratio 0/10	Male/female (%) 0/33.33
	Cholelithiasis with foci of intestinal metaplasia	9/0	30.00/0
	Cholelithiasis with adenomatous hyperplasia	0/3	0/10.00
	Cholelithiasis with foci of adenomatous hyperplasia	6/5	20.00/16.67
Intra-operative finding	Shrunken fibrotic gall bladder with stone (chronic cholecystitis)	15	50.00
	Polyploid mass	8	26.67
	Difficult cholecystectomy	4	13.33
	Thickened wall	3	10.00

Source: compiled by the authors

Among those with premalignant findings in HPE reports, 16 patients with elevated liver function test values and 4 patients with elevated glucose values were observed. HPE of these CaGB cases revealed that most were confined

to the gallbladder wall and did not exhibit signs of advanced disease, as the most frequently observed stage was Tis (Carcinoma in situ), with 11 patients (36.67%) falling into this category. T1a was the second most common stage,

accounting for 8 patients (26.67%), followed by T2b with 5 patients (16.67%). T2a included 4 patients (13.33%), and T1b had the smallest representation, comprising 2 patients (6.67%). This data reflects a spectrum of tumour stages, with a substantial number of patients presenting at early Tis and T1a stages, potentially offering better prospects for

intervention and management, while others are diagnosed at more advanced T2 stages, posing greater challenges for treatment and prognosis. Understanding this distribution is vital for tailoring treatment strategies based on the specific T-stage of the tumour, as per the American Joint Committee on Cancer (AJCC) 8th classification [12] (Fig. 3).

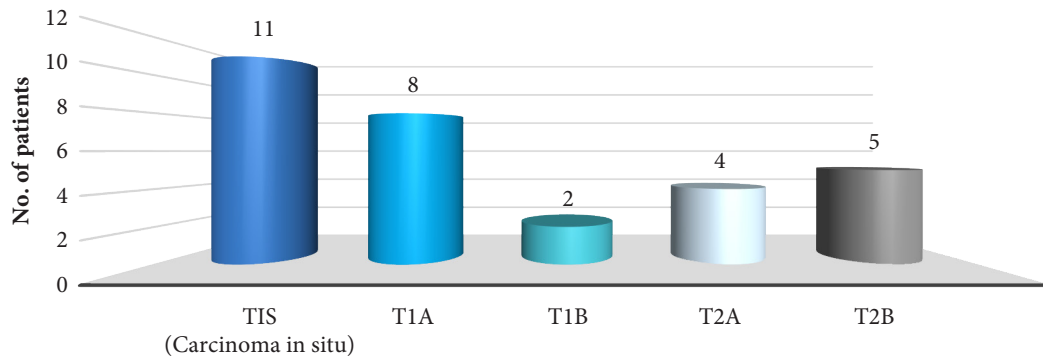


Figure 3. T-Stage of tumour of patients identified with CaGB

Source: compiled by the authors

In this study, the histopathological analysis indicated that all the missed gallbladder malignancies displayed characteristics consistent with adenocarcinoma. Among patients with pre-malignant lesions, predominant symptoms included abdominal pain, emphasizing its importance in gallbladder conditions. Missed malignancies were often confined to early stages (Tis and T1a), suggesting potential for effective intervention, but consistently displayed adenocarcinoma characteristics, highlighting the need for improved detection methods.

The study highlights a notable association between the prolonged duration of symptoms and the advancement of gallbladder malignancies. Patients enduring symptoms for over 40 weeks often presented with more advanced tumour stages. Additionally, the prevalence of specific symptoms, particularly abdominal pain, underscores its pivotal role as a predominant complaint among patients with missed malignancies. This emphasizes the significance of not overlooking common symptoms, as they might indicate underlying pathological conditions. This comprehensive examination and consideration of risk factors within patient assessments align with the broader goal of enhancing early detection strategies. It also emphasizes the imperative need for multidisciplinary collaboration among healthcare professionals to create more comprehensive and effective diagnostic and intervention protocols. Overall, the integration of these insights into clinical practice can substantially impact the timely detection and management of gallbladder conditions, potentially altering patient outcomes positively.

Moreover, the examination results, notably the ultrasound findings, exhibited certain patterns potentially associated with neglect or oversight of precancerous changes. A substantial portion of patients with missed gallbladder

malignancies displayed ultrasound features indicative of chronic cholecystitis or polypoid masses, which might have led to a misinterpretation or underestimation of the severity of the underlying conditions. Furthermore, the history of smoking, although not overwhelmingly prevalent, demonstrated a discernible trend among some patients. This association calls for a more comprehensive consideration of lifestyle factors and their potential impact on the development and progression of gallbladder malignancies.

Discussion

Gallbladder carcinoma typically develops in individuals between their 6th and 7th decades of life and shows a higher incidence among females [2, 12, 13], consistent with the data presented in the current study. The average age of GBC patients in the present study was 61.25 years, whereas M.H. Rather *et al.* [13] reported an average age of 60.07 years in their study. In this study, the prevalence of gall bladder cancer was observed to be 19.6%, which stands in contrast to the lower incidence rates documented in previous investigations, with reported ranges spanning from 0.2% to 3.3% [13-15]. In the current study, a significant proportion of patients diagnosed with CaGB were found to be from the lower middle class (40.00%), followed by the upper lower class (33.33%), the lower class (10.00%), the upper class (6.67%), and the upper middle class (3.3%). These socioeconomic distribution patterns were also noted by M.H. Rather *et al.* [13], who observed a similar trend, with most of their patients originating from lower socioeconomic backgrounds. They further posited that such socioeconomic challenges might lead to delays in accessing cholecystectomy, potentially contributing to the elevated incidence of GBC. In the current study, the majority of

CaGB patients exhibited a BMI falling within the range of 35 to 39.9 kg/m², underscoring a substantial association between a high BMI and CaGB. This association was consistent with the findings of M.H. Rather *et al.* [13], who reported that a significant portion of their patients had BMIs within the 35-39.9 kg/m² range.

Moreover, the current study revealed a substantial history of cigarette smoking, particularly among male patients. In this study, the dominant symptom reported was abdominal pain, accounting for 86.67% of cases, tailed by weight loss, jaundice, and vomiting. The duration of symptoms ranged from a minimum of 0-10 weeks to a maximum of over 40 weeks before undergoing surgical procedures. Similarly, M.H. Rather *et al.* [13] also found that abdominal pain was the predominant symptom, affecting over 90% of their patients. Clinically, patients in study by N. Singh *et al.* [14] commonly presented with right upper quadrant abdominal pain and vomiting, with durations spanning from two to eight months. Pain in the right upper quadrant, loss of appetite, nausea, and vomiting were the most frequently reported symptoms among individuals experiencing these issues, consistent with the present study's findings. Notably, late-stage GBC often exhibits symptoms distinct from typical biliary colic, often including malaise and weight loss [16]. In a different study by V. Jha *et al.* [2], the primary symptom observed in the majority of patients was pain in the right hypochondriac region, experienced by 89% of the study participants. Subsequently, a smaller proportion reported symptoms of nausea and vomiting (6%), while epigastric pain was noted in 3% of cases. In this study, the preoperative USG of patients with CaGB revealed various findings, including the presence of stones in 40.00% of cases, adenomyomatosis in 26.67% of cases, wall thickening combined with stones in 13.33% of cases, multiple stones in 10.00% of cases, and wall thickening alongside a single stone in 10.00% of cases. It's noteworthy that the majority of patients' ultrasonography results indicated the presence of either stones or adenomyomatosis [13]. Among the patients in the study by V. Jha *et al.* [2], chronic calculous cholecystitis was the most frequently observed condition in 3,765 patients (78.43%). Chronic acalculous cholecystitis was reported in 960 patients (20%), while xanthogranulomatous cholecystitis was observed in 40 cases (0.83%). Additionally, 10 cases (0.20%) presented with mucocele, 4 cases (0.08%) exhibited adenomyomatosis, and a singular instance of a cholesterol polyp was identified. Gallstones are significant comorbid risk factors (70-98%) and the incidence of CaGB related to cholelithiasis ranges from 0.3% to 12% [2, 4, 14]. Oestrogen has been implicated as a factor leading to increased cholesterol supersaturation in bile, potentially contributing to the pathogenesis of CaGB associated with gallstones [17]. Gallstones were observed in 74% of all neoplastic cases, consistent with the findings of the studies mentioned above. Remarkably, individuals with symptomatic gallstones are at a heightened risk of developing CaGB compared to those with asymptomatic gallstones,

with cholesterol stones emerging as the predominant cause of symptomatic gallstone formations [18].

The current study's intraoperative observations of patients with CaGB revealed diverse findings. Approximately half of the patients presented with a shrunken, fibrotic gallbladder containing stones, while the remaining patients exhibited polypoid masses (26.67%), challenging cholecystectomies (13.33%), and gallbladder walls with a thickness of ≥ 10 mm (10%). Similarly, in the study by N. Singh *et al.* [14], most CaGB cases were characterised by the presence of gallstones and variable wall thickness, as observed both through imaging and gross morphology. Upon gross inspection, 55% of the specimens displayed gallbladder wall thickening in 11 out of 20 cases, while mucosal ulceration was found in two cases (10%). Notably, in 35% of instances, there were no discernible preoperative or macroscopic indications suggestive of malignancy [2]. The majority of CaGB cases in the current study, upon HPE, did not manifest advanced disease characteristics and were primarily confined to the gallbladder wall. In the present study, Tis (Carcinoma in situ) was the most frequently encountered stage, with T1a being the second most common stage. Correspondingly, M.H. Rather *et al.* [13] observed that 5 cases fell within the Tis stage, while 4 cases were categorised as T1a. Similar findings were reported by V.P. Bastiaenen *et al.* [19], B.J.G.A. Corten *et al.* [20]. V. Jha *et al.* [2] identified two cases of CaGB at the pathological tumour 2 (pT2) stage. In the case of Tis and pT1a tumours, simple cholecystectomy is typically sufficient, and the 5-year survival rate is nearly 100%. However, for pT1b tumours, more extensive radical resection is recommended. For pT2 tumours, there is a notable enhancement in the 5-year survival rate, increasing from 20% to 70% when a straightforward cholecystectomy is succeeded by a comprehensive radical cholecystectomy subsequent to the diagnosis of CaGB. Hence, HPE should be performed on all surgically resected gallbladders since it is the sole diagnostic tool capable of accurately detecting CaGB, ultimately enhancing patient survival when compared to CaGB [2]. The present study highlights the complexity of accurately anticipating malignancy in all samples solely relying on imaging or macroscopic features. It emphasizes the importance of evaluating the depth of invasion in CaGB since surgical approaches are contingent upon accurate staging. In the current research, HPE revealed that all cases of gallbladder malignancies exhibited characteristics consistent with adenocarcinoma. These findings align with those from a prior study [10]. Adenocarcinoma of the pancreaticobiliary subtype is the most prevalent subtype observed in histopathological examinations, constituting around 90-95% of all observed gallbladder malignancies. Subsequently, squamous, or adenosquamous carcinomas emerge as the subsequent prevalent subtypes [1, 16, 21]. Most malignant cases in the present study also manifested characteristics consistent with adenocarcinoma, which is consistent with the scientists' findings N. Singh *et al.* [14]. Gallbladder carcinoma primarily affects individuals in their 6th decade of life, with

higher incidence in females. Socioeconomic factors contribute to delayed access to cholecystectomy. Adenocarcinoma is the prevalent subtype, emphasizing the need for accurate staging for optimal treatment.

Conclusions

Ignorance or neglect of certain risk factors can significantly impact the progression from precancerous lesions to malignancy. The study underscores the significance of vigilant assessment, particularly in individuals aged over 50, belonging to the lower middle class, and presenting with abdominal pain, which emerged as a predominant and early symptom in missed gallbladder malignancies. Notably, weight loss, jaundice, and vomiting, though less frequent, were also reported, emphasizing the need for considering diverse clinical presentations for early detection. Histopathological findings revealed premalignant lesions predominantly in females with cholelithiasis and intestinal metaplasia. The prevalence of adenocarcinoma in missed gallbladder malignancies calls for increased awareness and thorough evaluation, with a diverse spectrum of tumour stages observed. The distribution of early and advanced

stages highlights the importance of tailored treatment strategies based on the specific T-stage, to improve intervention and management outcomes. Overall, these findings stress the critical importance of comprehensive assessment and timely diagnosis for effective management of gallbladder malignancies. One limitation of this study is its retrospective nature, which relies on historical patient data. This could result in potential data gaps or inconsistencies due to the absence of real-time data collection. Additionally, the study's relatively small sample size of 30 patients may limit the generalizability of the findings to a larger population. Future study on gallbladder malignancies should prioritize prospective studies with a larger, diverse patient cohort for real-time data collection and a longitudinal approach, fostering collaboration among healthcare institutions to improve early diagnosis and intervention strategies.

Acknowledgements

None.

Conflict of Interest

All authors declare no conflict of interest.

References

- [1] Di Mauro D, Orabi A, Myintmo A, Reece-Smith A, Wajed S, Manzelli A. Routine examination of gallbladder specimens after cholecystectomy: A single-centre analysis of the incidence, clinical and histopathological aspects of incidental gallbladder carcinoma. *Discov Oncol.* 2021;12(1):e4. DOI: [10.1007/s12672-021-00399-5](https://doi.org/10.1007/s12672-021-00399-5)
- [2] Jha V, Sharma P, Mandal KA. Incidental gallbladder carcinoma: Utility of histopathological evaluation of routine cholecystectomy specimens. *South Asian J Cancer.* 2018;7(1):21–23. DOI: [10.4103/2278-330X.226802](https://doi.org/10.4103/2278-330X.226802)
- [3] Lundgren L, Muszynska C, Ros A, Persson G, Gimm O, Valter L, et al. Are incidental gallbladder cancers missed with a selective approach of gallbladder histology at cholecystectomy? *World J Surg.* 2018;42(4):1092–99. DOI: [10.1007/s00268-017-4215-0](https://doi.org/10.1007/s00268-017-4215-0)
- [4] Roa JC, Basturk O, Adsay V. Dysplasia and carcinoma of the gallbladder: Pathological evaluation, sampling, differential diagnosis and clinical implications. *Histopathology.* 2021;79(1):2–19. DOI: [10.1111/his.14360](https://doi.org/10.1111/his.14360)
- [5] Rawla P, Sunkara T, Thandra KC, Barsouk A. Epidemiology of gallbladder cancer. *Clin Exp Hepatol.* 2019;5(2):93–2. DOI: [10.5114/ceh.2019.85166](https://doi.org/10.5114/ceh.2019.85166)
- [6] Roa JC, García P, Kapoor VK, Maithel SK, Javle M, Koshiol J. Gallbladder cancer. *Nat Rev Dis Primers.* 2022;8(1):e69. DOI: [10.1038/s41572-022-00398-y](https://doi.org/10.1038/s41572-022-00398-y)
- [7] Gupta V, Chandra A, Gupta V, Patel R, Dangi A, Pai A. Gallbladder perforation: A single-center experience in north India and a step-up approach for management. *Hepatobiliary Pancreat Dis Int.* 2022;21(2):168–74. DOI: [10.1016/j.hbpd.2021.08.011](https://doi.org/10.1016/j.hbpd.2021.08.011)
- [8] Dutta U, Bush N, Kalsi D, Popli P, Kapoor VK. Epidemiology of gallbladder cancer in India. *Chin Clin Oncol.* 2019;8(4):e33. DOI: [10.21037/cco.2019.08.03](https://doi.org/10.21037/cco.2019.08.03)
- [9] Kalra N, Gupta P, Singhal M, Gupta R, Gupta V, Srinivasan R, et al. Cross-sectional imaging of gallbladder carcinoma: An update. *J Clin Exp Hepatol.* 2019;9(3):334–44. DOI: [10.1016/j.jceh.2018.04.005](https://doi.org/10.1016/j.jceh.2018.04.005)
- [10] Vuthaluru S, Sharma P, Chowdhury S, Are C. Global epidemiological trends and variations in the burden of gallbladder cancer. *J Surg Oncol.* 2023;128(6):980–88. DOI: [10.1002/jso.27450](https://doi.org/10.1002/jso.27450)
- [11] The World Medical Association. Declaration of Helsinki: Ethical Principles for Medical Research Involving Human Subjects [Internet]. Available from: <https://www.wma.net/what-we-do/medical-ethics/declaration-of-helsinki/>
- [12] Amin MB, Greene FL, Edge SB, Compton CC, Gershenwald JE, Brookland RK, et al., editors. *AJCC Cancer Staging Manual* [Internet]. 8th ed. Cham: Springer; 2017 [cited 2023 Dec 27]. 1032 p. Available from: <https://link.springer.com/book/9783319406176>
- [13] Rather MH, Malik NA, Gilkar IA, Jeelani S, Mushtaq U, Peer JA, et al. Clinical study of incidental Gall bladder malignancy after elective cholecystectomy. A retrospective study. *J Evid Based Med Healthc.* 2019;6(14):1145–49. DOI: [10.18410/jebmh/2019/239](https://doi.org/10.18410/jebmh/2019/239)
- [14] Singh N, Zaidi A, Kaur R, Kaur J, Nijhawan VS. Incidental gallbladder neoplasms: A growing global burden. *Cureus.* 2022;14(6):e25805. DOI: [10.7759/cureus.25805](https://doi.org/10.7759/cureus.25805)

- [15] Poudel R, Shah A. Incidence of incidental gall bladder cancer and role of routine histopathological examination in cholecystectomies specimens for benign disease. *J Nepal Health Res Counc.* 2020;18(3):547–50. DOI: [10.33314/jnhrc.v18i3.1974](https://doi.org/10.33314/jnhrc.v18i3.1974)
- [16] Halaseh SA, Halaseh S, Shakman R. A review of the etiology and epidemiology of gallbladder cancer: What you need to know. *Cureus.* 2022;14(8):e28260. DOI: [10.7759/cureus.28260](https://doi.org/10.7759/cureus.28260)
- [17] Zu Y, Yang J, Zhang C, Liu D. The pathological mechanisms of Oestrogen-induced cholestasis: Current perspectives. *Front Pharmacol.* 2021;12:761255. DOI: [10.3389/fphar.2021.761255](https://doi.org/10.3389/fphar.2021.761255)
- [18] Valle JW, Kelley K, Nervi B, Oh DY, Zhu AX. Biliary tract cancer. *Lancet.* 2021;397(10272):428–44. DOI: [10.1016/S0140-6736\(21\)00153-7](https://doi.org/10.1016/S0140-6736(21)00153-7)
- [19] Bastiaenen VP, Tuijje JE, van Dieren S, Besselink MG, van Gulik TM, Koens L, et al. Safe, selective histopathological examination of gallbladder specimens: A systematic review. *Br J Surg.* 2020;107(11):1414–28. DOI: [10.1002/bjs.11759](https://doi.org/10.1002/bjs.11759)
- [20] Corten BJGA, Alexander S, van Zwam PH, Leclercq WKG, Roumen RMH, Slooter GD. Outcome of surgical inspection of the gallbladder in relation to final pathology. *J Gastrointest Surg.* 2019;23(6):1130–34. DOI: [10.1007/s11605-018-3921-8](https://doi.org/10.1007/s11605-018-3921-8)
- [21] Geramizadeh B, Kashkooe A. Incidental gall bladder adenocarcinoma in cholecystectomy specimens; a single center experience and review of the literature. *Middle East J Dig Dis.* 2018;10(4):249–53. DOI: [10.15171/mejdd.2018.118](https://doi.org/10.15171/mejdd.2018.118)

Пропущена злоякісна пухлина жовчного міхура: результат ігнорування факторів схильності

Санья Бхушан

Бакалавр медицини, бакалавр хірургії, ординатор
Медичний коледж FH
283201, Railway over Bridge, NH-2, м. Агра, Індія
<https://orcid.org/0009-0008-1247-1818>

Абхінав Міттал

Бакалавр медицини, бакалавр хірургії, доцент
Медичний коледж FH
283201, Railway over Bridge, NH-2, м. Агра, Індія
<https://orcid.org/0009-0003-0979-4484>

Мірза Фараз Бег

Бакалавр медицини, бакалавр хірургії, асистент
Медичний коледж FH
283201, Railway over Bridge, NH-2, м. Агра, Індія
<https://orcid.org/0009-0005-2314-2102>

Ааканша Агарвал

Бакалавр медицини, бакалавр хірургії, ординатор
Медичний коледж FH
283201, Railway over Bridge, NH-2, м. Агра, Індія
<https://orcid.org/0009-0007-8839-8840>

Анотація. Недооціненість поширеності карциноми жовчного міхура, яка є домінуючою формою злоякісного захворювання жовчних шляхів, представляє суттєву загрозу через її безсимптомний прогрес. Таким чином, метою роботи було проаналізувати клінічні, імеджингові та інтраопераційні результати у випадках карциноми жовчного міхура. Це ретроспективне дослідження проводилося з вересня 2022 року по березень 2023 року на кафедрі загальної хірургії Медичного коледжу FH. У ньому взяли участь 153 пацієнти, які були визнані придатними для операції та пройшли процедуру. Пацієнтам були проведені різні діагностичні та лабораторні тести, включаючи аналіз крові, випадкове визначення рівня цукру в крові, вірусні маркери, рентгенографію грудної клітки, функціональні проби нирок та печінки, а також ультразвукове дослідження всієї черевної порожнини. Зразки жовчного міхура були направлені на гістопатологічне дослідження, результати якого були зафіксовані та проаналізовані. У гістопатологічних звітах 30 зі 153 пацієнтів, які отримували хірургічне лікування, відмічено ознаки передракових уражень. Частота захворювання виявилася вищою серед жінок. Серед цих 30 пацієнтів 22 мали діагностовану ультразвуковим дослідженням жовчнокам'яну хворобу з гострим або хронічним холециститом, тоді як 8 пацієнтів мали жовчнокам'яну хворобу без потовщення стінки жовчного міхура. Крім того, 9 з цих пацієнтів мали фокальну/неправильну/товщину стінки ≥ 10 мм. Загалом у 16 пацієнтів спостерігалася підвищена активність функцій печінки, а у 4 – підвищений рівень глюкози серед тих, у кого в гістопатологічних звітах було виявлено передракові ураження. Це дослідження підкреслює невлесимий характер раку жовчного міхура, наголошуючи на необхідності всебічної, ретельної передопераційної оцінки та мультидисциплінарного підходу для забезпечення раннього виявлення та лікування

Ключові слова: лапароскопічна холецистектомія; карцинома жовчного міхура; гістопатологічне дослідження; комп'ютерна томографія