



Dupuytren's contracture treated with collagenase *Clostridium histolyticum*

Martina Vidova Ugurbas*

Doctor of Medicine, Associate Professor
Pavol Jozef Šafárik University in Košice
04 180, 2 Srobarova Str., Kosice, Slovak Republic
<https://orcid.org/0000-0003-4620-6031>

Abstract. Treatment of Dupuytren's contracture improves the quality of life of patients, but standard open fasciectomy surgery is traumatic and requires long-term rehabilitation. The study aimed to determine whether injectable treatment with collagenase preparations was effective in comparison with open fasciectomy. Forty patients were examined. Of these, 15 were treated with *Clostridium histolyticum* collagenase preparations (the main group), and 25 underwent limited fasciectomy (the control group). In 11 (73.3%) patients of the main group, restoration of mobility of the affected joints was achieved after the first injection, in 3 (20%) – after the second, and in 1 (6.7%) – after the third. Patients in the main group remained able to work after treatment and did not require rehabilitation; the function of the upper limb was fully restored on the day of intervention. During the observation period, 12 (80%) patients in the main group were concerned about dry skin at the intervention site, and 5 (33.3%) patients were concerned about itching and discolouration of the skin at the intervention site. In 25 (100%) patients of the control group, joint mobility was fully restored. The ability to use the hand after surgery in patients of the control group was limited for 6 (4.5; 10) days. All patients in the control group required rehabilitation to relieve stiffness and restore the functional capabilities of the hand. The period of disability in these patients lasted 16 (12; 24.5) days. 11 (44%) patients had complaints of pain or discomfort in the intervention area during the follow-up, and 24 (96%) patients were bothered by itching. Satisfaction with the choice of treatment method in the main group was more frequent compared to the control group. Relapses during the observation period were absent in both groups. Thus, the efficacy of *Clostridium histolyticum* collagenase preparations are comparable to the results of surgical treatment. Minimally invasive treatment is optimal for patients with mild disease, as well as for those who have a low risk of contracture recurrence. The results of this study can be useful for surgeons when choosing the optimal method of treating Dupuytren's contracture

Keywords: palmar fibromatosis; minimally invasive intervention; hand surgery; open fasciectomy; clinical trial; patient management

Introduction

Dupuytren's contracture is a chronic connective tissue disease. This pathology occurs as a result of fibrous changes in the palmar fascia, a layer of connective tissue that covers the tendons on the palm side of the hand. These changes lead to shortening and tightening of the fascia, which in turn limits the mobility of the fingers. According to an epidemiological study by N. Salari *et al.* [1], the prevalence of Dupuytren's contracture in European countries is approximately 10%. In the initial stage of the

disease, patients complain of nodule-like formations on the palmar surface of the hand. Such nodules are not painful and do not limit the mobility of the limb. However, the disease gradually progresses, and the nodules turn into fibrous bands, which causes a flexion contracture. Most often, contractures are formed on the fourth or fifth finger, but there are also cases of multiple contractures. Although pain in patients with this pathology is not common, the contracture significantly impairs their quality of

Suggest Citation:

Ugurbas MV. Dupuytren's contracture treated with collagenase *Clostridium histolyticum*. Int J Med Med Res. 2023;9(1):39–46.
DOI: 10.61751/ijmmr.2413-6077.2023.1.39

*Corresponding author



life, as it limits their ability to perform daily activities, including self-care and work capacity [2].

The aetiology of the disease is not known for certain. H. Ruettermann *et al.* [3] in a literature review conclude that about 80% of cases of Dupuytren's contracture are associated with a genetic predisposition. Other risk factors include diabetes mellitus, liver disease, and epilepsy. According to a study by J.N. Aleksandar *et al.* [4], among patients with diabetes mellitus, the risk is increased by factors such as age, duration of the disease, poor blood glucose control and hypokalaemia. L. Murinová *et al.* [5] note that Dupuytren's contracture can be an occupational disease if it develops after prolonged work with vibrating tools. Alcohol consumption is also a significant risk factor for the development of pathology, unlike smoking [6, 7].

The treatment of Dupuytren's contracture is complex. It is difficult to slow down the development of the pathology even with timely diagnosis. According to the R. Sanjuan-Cervero [8], physiotherapy is not effective, but radiotherapy and corticosteroid injection therapy can slow the formation of the contracture, reduce patient discomfort, and reduce the likelihood of future surgical treatment. However, further research is needed to prove the effectiveness of these methods. According to the British Medical Journal guidelines, updated in 2023, patients with one or more Dupuytren's nodules are recommended to be actively monitored with the recommended frequency of visits to the doctor every 6 months. A more active approach to treatment is indicated for patients with Dupuytren's contracture who have a functional impairment [9]. Minimally invasive treatments (injections of *Clostridium histolyticum* collagenase, needle aponeurotomy, or percutaneous fasciotomy) are recommended for patients with a range of motion of up to 30°. In patients with more severe extension disorders, open fasciectomy may also be used.

According to H. Ruettermann *et al.* [3], limited open fasciectomy is the "gold standard" for the treatment of Dupuytren's contracture, as it allows for restoring hand function in the vast majority of cases. After limited fasciectomy, the incidence of contracture recurrence is lower than after needle aponeurotomy or percutaneous fasciotomy. The disadvantage of this method is high tissue trauma during the operation, which leads to a long period of disability and requires rehabilitation. Injectable therapy with *Clostridium histolyticum* collagenase preparations is much less traumatic, so patients recover faster after this treatment and do not require long-term rehabilitation. However, the effectiveness of this treatment compared to invasive methods requires further study [8].

Thus, Dupuytren's disease significantly worsens the quality of life of patients and causes economic losses for the state, and etiological treatment and prevention are impossible due to the multifactorial nature of the pathology. Standard surgical methods of treatment have significant drawbacks, but for the routine use of minimally invasive treatment, it is necessary to investigate whether it is

effective in comparison with traditional invasive methods. The study was aimed at comparing the treatment of Dupuytren's contracture with *Clostridium histolyticum* collagenase preparations and open fasciectomy.

Materials and Methods

The study was conducted at the Department of Plastic, Reconstructive and Aesthetic Surgery of the Louis Pasteur University Hospital, which is part of the Faculty of Medicine of Pavol Jozef Šafárik University, Kosice, Slovakia. The study period was from January 2021 to May 2023.

The study included 40 patients, of whom 23 (57.5%) were men and 17 (42.5%) were women. The age of the patients was 56 (46.5; 69) years. The main group included 15 patients (9 (60%) men and 6 (40%) women), their age was 53.5 (44; 69.5) years. In 8 (53.3%) patients, the extension limitation did not exceed 50°, which characterised a relatively early stage of Dupuytren's contracture, and in the remaining 7 (46.7%) patients, the limitation was more pronounced and exceeded 50°.

Patients in the main group received injectable treatment with enzyme preparations isolated from the bacterium *Clostridium histolyticum*. *Clostridium histolyticum* collagenase contains two classes of enzymes: AUX-I and AUX-II. Collagenase class I (AUX-I) cleaves the end fragments of the collagen chain, respectively, and collagenase class II (AUX-II) cleaves the inner segment of this chain. In all cases, the drug was injected into the most proximal part of the fibrous cord. It was extremely important to prevent skin contact with the drug, as this could lead to damage to the skin. In the case when two joints (metacarpophalangeal and proximal interphalangeal) were involved in the pathological process on one finger, the drug was initially injected only into the metacarpophalangeal joint. This approach made it possible to achieve extension of the affected finger in both joints at once, while reducing trauma to the hand tissues, which, although minimal, still occurs even with a sparing approach to treatment.

The inclusion criteria were as follows: the presence of Dupuytren's contracture of the second degree or higher, which was assessed as restriction in the extension of the metacarpophalangeal and/or proximal interphalangeal joints of at least one finger of the upper limb (excluding the thumb), with patients having restriction in the extension of at least one finger, while the presence of Dupuytren's nodules alone was not a reason for inclusion in the study; age over 18 years; consent to participate in the study.

The study excluded patients with severe Dupuytren's contracture (extension limitation of more than 135°), as well as patients with concomitant musculoskeletal pathology, including osteoarthritis, gout, rheumatoid or gouty arthritis, ankylosing spondylitis, neuromuscular pathology of the hand; pregnant women; bleeding patients and those who are constantly taking anticoagulants. The study also did not include patients with previous surgical interventions on the affected hand, whether as a result of Dupuytren's contracture treatment or for any other

reason, as well as those who had already received treatment with *Clostridium histolyticum* collagenase. Patients with diabetes mellitus were also excluded from the study, as differential diagnosis of Dupuytren's contracture and diabetic hyperpathia may be difficult in some cases. Instead, a history of trauma to the affected hand or a hereditary factor was not considered a criterion for excluding patients from the study.

The choice of treatment method (surgical or injection) for each patient was determined by the doctor based on the recommendations of the British Medical Journal, as well as considering the individual characteristics of the patient [9]. Factors such as the presence of contraindications to surgery (severe somatic pathology, drug allergies), age, and the patient's preference for treatment were considered. Patients decided on the treatment method after receiving detailed information about the benefits and risks of each method.

Before use, the *Clostridium histolyticum* collagenase preparation in the amount of 0.58 mg was diluted in 0.25 or 0.2 mL of saline (respectively, for metacarpophalangeal and proximal interphalangeal joints), after which it was injected into the affected joint. The drug remained at the injection site for 24 hours, after which, using local anaesthetics, the patient was allowed to extend the finger, which was accompanied by the destruction of the contracture. The injection therapy with *Clostridium histolyticum* collagenase preparations, followed by breaking the contracture and releasing one or more fingers, was performed in the manipulation room or directly in the doctor's office. The surgical intervention involved open fasciectomy and was performed in the operating room.

After treatment, all patients were followed up for 12 months. Initially, monitoring of the patient's clinical condition immediately after the intervention took place daily and for patients who received injection therapy lasted several days, as the treatment was outpatient, while for those patients who received surgical treatment – from a week, as these patients were hospitalised. During the follow-up, the following methods were used to assess the patient's condition: collection of complaints and anamnesis data (including information on the duration of disability), assessment of the patient's objective status, including local status, and measurement of the degree of restriction in finger extension.

Data were collected, tabulated using MS excel and later presented as percentages and proportions. The design of this study was approved by the University Biomedical Ethics Committee and agreed with the legal department and medical law specialists. The study complied with the basic bioethical standards, such as the principle of autonomy of research participants, the absence of harm to them, the existence of research benefits for society that outweigh the possible risks to patients participating in the study, as well as the principle of justice and non-discrimination [10]. All patients agreed to the processing of personal data and gave voluntary informed consent to participate in the study.

Results

The technique of injecting *Clostridium histolyticum* collagenase into the affected tendon cord includes three stages and is shown in detail in Figures 1-3. The doctor performing the intervention makes only one puncture of the skin and then directs the drug in different directions, changing the angle of the needle.

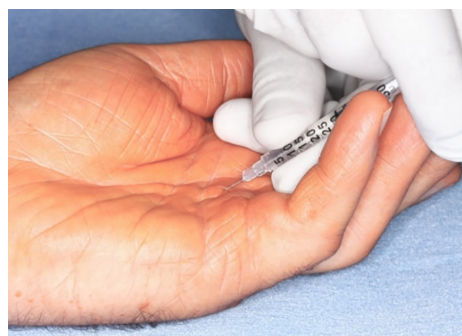

Figure 1. Injection of *Clostridium histolyticum* collagenase into the fibrotic ligament, the beginning of the intervention

Source: photographed by the author

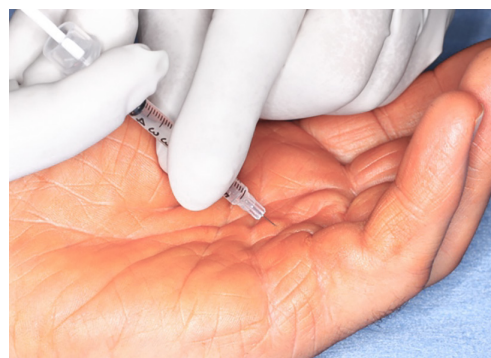

Figure 2. Injection of *Clostridium histolyticum* collagenase into the fibrotic ligament, a continuation of intervention

Source: photographed by the author

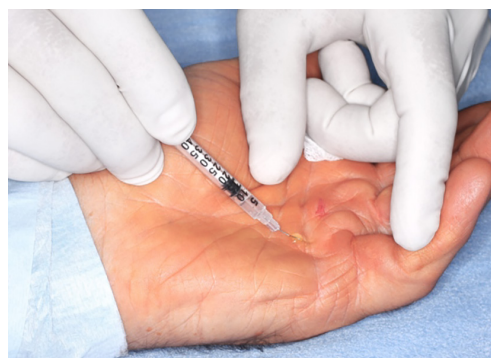

Figure 3. Injection of *Clostridium histolyticum* collagenase into the fibrotic ligament, end of the intervention

Source: photographed by the author

As mentioned earlier, the procedure for breaking the Dupuytren's contracture was performed the day after the injection using local anaesthesia. The technique of local anaesthesia and the positive results of the treatment of Dupuytren's contractures of four fingers are shown in Figures 4 and 5.

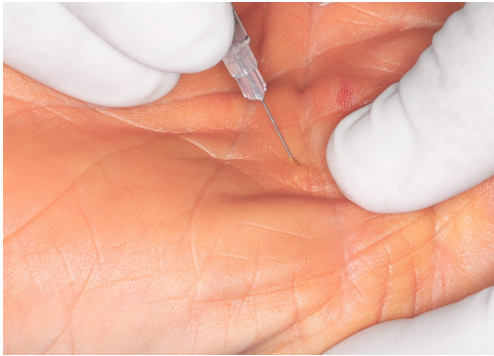


Figure 4. Use of local anaesthesia the day after the injection of *Clostridium histolyticum* collagenase
Source: photographed by the author

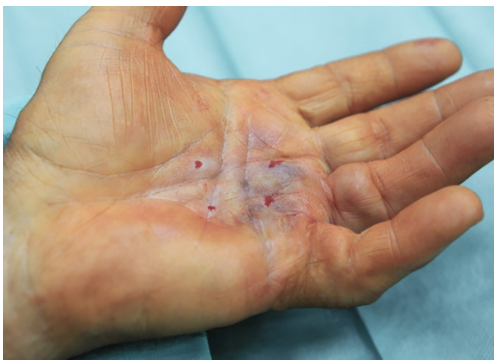

Figure 5. Palm surface of the hand after treatment of Dupuytren's contracture of the index, middle, ring fingers and little finger with collagenase of *Clostridium histolyticum*
Source: photographed by the author

In 11 (73.3%) patients of the main group, the first and only injection of *Clostridium histolyticum* collagenase demonstrated its effectiveness, which allowed to break the fibrous cord and achieve freedom of movement in the affected finger or several fingers. However, for 4 (26.7%) patients, the initial application of *Clostridium histolyticum* collagenase was ineffective and did not allow for the complete release of one or more fingers. All patients who failed the first treatment attempt were offered a second intervention at intervals of at least 4 weeks, to which all patients agreed.

Repeated intervention was performed using an identical methodology and was effective in 3 out of 4 patients who did not achieve the desired treatment result during the initial intervention. The patient whose contracture rupture was not possible after the second injection was offered a third session of injection therapy. He agreed that the

treatment was performed 4 weeks later and was successful: the patient fully regained freedom of movement in the affected joint. In the early postoperative period, patients quickly regained the ability to use the limb undergoing the intervention. The pain in the projection of the ruptured contracture, although disturbing, was well relieved by taking non-steroidal anti-inflammatory drugs. Within one to two days after rupture of the fibrous cord, the pain decreased to the extent that it did not require painkillers. In 6 (40%) patients, oedema of the hand undergoing the intervention was observed. The swelling was mild and disappeared in a few days.

Patients regained the functionality of their upper limbs almost immediately after contracture correction. They did not need rehabilitation measures or long-term medical supervision. The patients' work capacity was preserved, so they could resume their jobs after treatment. The course of the postoperative period after the second and third injection therapy sessions did not differ from that after the first session. After the second and third injections, the pain was moderate in all cases and resolved after taking non-steroidal anti-inflammatory drugs. Swelling of the hand was observed in 1 patient after the second injection of *Clostridium histolyticum* collagenase preparations. The control group included 25 patients (including 14 (56%) men and 11 (44%) women), the age of the study participants in this group was 57 (48; 73.5) years). Patients in the control group underwent surgical treatment by limited open fasciectomy.

Limited fasciectomy was performed using regional anaesthesia, including brachial plexus block. To access the contracture, zigzag incisions were made along the natural palmar and finger folds. This approach provided adequate access to the aponeurosis while preventing unnecessary tissue trauma. The limited fasciectomy involved the removal of only those tissues that were macroscopically assessed as pathological during the operation, in contrast to open dermofasciectomy, when the entire palmar aponeurosis is removed regardless of the degree of damage. After the surgery, the wound remained open without the use of skin grafts for closure. This approach reduced postoperative pain and improved early recovery of hand function. During the operation, complications such as nerve and vascular damage are possible, although extremely rare (1-2%). Intraoperative complications are associated with the formation of compacted bands at the site of fascial bundles. Some tapes can distort neurovascular structures, creating a risk of damage during surgical procedures.

Early postoperative complications, which occur more frequently (up to 20% of cases), are haematoma formation and wound infection [3]. The patients who participated in this study did not have any complications both during surgery and during the rehabilitation period. The absence of complications was facilitated by careful observance of septic and antiseptic rules during surgery, careful planning of the course of operations and development of their techniques, prophylactic use of antibiotics perioperatively and careful monitoring of the wound with regular treatment with antiseptic and healing agents. However, despite the

absence of complications, all patients in the control group experienced pain in the operated hand, swelling and inability to use the upper limb in the early postoperative period. Discomfort symptoms decreased after taking non-steroidal anti-inflammatory drugs, elevating the limb, and applying cold to it, but the effectiveness of these drugs was temporary and did not affect functional impairment. The need for painkillers in patients of the control group persisted for about a week. The operated limb was fixed in a functional position in the early postoperative period, which ensured 45-70° flexion in the metacarpophalangeal joints and extension in the proximal and distal interphalangeal joints. The duration of the hand immobilisation period in patients of the control group was 6 (4.5; 10) days.

In the first few days after surgery, patients were referred for a consultation with a physiotherapist to develop an individual rehabilitation plan. Early start of rehabilitation is extremely important, as it allows for the fastest possible restoration of the function of the operated limb, preservation of the range of motion achieved during the operation, and prevention of stiffness. At the same time, the load should be gentle, as excessive exercise can slow down tissue regeneration and healing. Patients are also advised to temporarily limit driving and to keep the arm elevated even at rest. All patients who participated in the study were subsequently followed up. Patients in the main group did not have any visual damage to the skin after the puncture sites healed, and no pain or swelling was observed. During the survey, it was found that the quality of life after treatment improved in all 15 (100%) patients of the main group. Since the patients' preferences were considered when choosing a treatment method, they were asked during the follow-up examination whether they regretted their choice. All 15 (100%) patients were satisfied with their choice. 9 (60%) patients would recommend this method to their relatives if necessary, and 6 (40%) patients were undecided at the time of the examination. During the entire observation period, no relapses were recorded in the main group.

After treatment with *Clostridium histolyticum* collagenase preparations, there is a risk of developing several serious complications. First of all, it is a tendon rupture that requires repeated surgical intervention for reconstruction. No tendon ruptures were observed in the patients of this study. The risk of bleeding during this intervention is minimal, provided that the patient has no haematological pathology and does not take anticoagulants. On the contrary, antiplatelet medication is safe and does not increase the risks of the procedure. The second, but no less important, is algodystrophy, which is also known as Zudeck's syndrome, complex regional pain syndrome type I or reflex sympathetic dystrophy. Patients with algodystrophy suffer from pain, hypersensitivity of the hand skin to any stimuli, pale skin or its hyperaemia, dryness and itching, swelling, and muscle weakness.

During the examination in the dynamics, 12 (80%) patients in the main group complained of dry skin in the area of the palm where the puncture was performed, while

5 (33.3%) patients had minor skin discoloration and itching. However, these symptoms decreased over time and were well-corrected with the use of skincare products. Thus, there were minor trophic disorders, and such a serious complication as Zudeck's syndrome was absent in these patients during the observation period. In 17 (68%) patients of the control group, there were complaints of periodic discomfort in the intervention area. Swelling of the operated hand was observed in 11 (44%) patients and itching in the postoperative wound area in 24 (96%) patients. 21 patients reported complaints of stiffness in their movements after stopping rehabilitation activities or improper exercise. During the survey, all 25 (100%) patients in the control group had improved quality of life. However, only 8 (32%) were ready to recommend limited fasciectomy to their relatives in case of need, 12 (48%) patients were undecided, and 5 (20%) said they would not recommend this intervention to anyone. When asked about satisfaction with the choice of treatment method, 11 (44%) patients were dissatisfied. Disability in patients of the control group was 16 (12; 24.5) days.

When the postoperative wounds had healed, patients in the control group were concerned about the formation of postoperative scars, associated cosmetic defects and a feeling of tightness in the skin. However, in all cases, the functional effect achieved by the treatment was maintained. Thus, the recovery of patients after treatment with *Clostridium histolyticum* collagenase preparations was relatively rapid, and no serious complications were recorded. In contrast, recovery after surgical treatment was more difficult and lengthier.

Discussion

Over the past 10 years, a significant amount of data has been collected on various treatments for Dupuytren's contracture. Several literature reviews with meta-analyses were conducted to systematise this information. All of these reviews confirm the effectiveness of treatment with *Clostridium histolyticum* collagenase preparations compared to placebo.

In particular, M. Brazzelli *et al.* [11] conducted a meta-analysis of the results of five randomised clinical trials involving 493 patients. After treatment with *Clostridium histolyticum* collagenase preparations, the extension limitations caused by contracture were significantly reduced compared to the placebo group. It is clear that the number of side effects from the use of active drugs was higher than in the placebo group, but most of these symptoms were not serious. Out of 493 patients, only 4 (0.8%) experienced serious complications of the procedure: three cases of tendon rupture and one case of complex regional pain syndrome. This study did not directly compare *Clostridium histolyticum* collagenase preparations with placebo. However, the absence of serious complications confirms the meta-analysis data, which indicates that such complications are extremely rare and account for less than 1%. The clinical efficacy of injectable therapy with *Clostridium histolyticum* collagenase preparations is also confirmed by other systematic reviews of the literature with meta-analyses [12, 13].

E. Soreide *et al.* [14] analysed 20 clinical trials involving a total of 1584 patients to compare the effectiveness of three treatments for Dupuytren's contracture: percutaneous needle aponeurotomy, limited fasciectomy, and injection therapy with *Clostridium histolyticum* collagenase. The researchers concluded that injection therapy was better tolerated by patients compared to surgical treatments. However, it was found that patients treated with *Clostridium histolyticum* collagenase products had a significantly higher recurrence of Dupuytren's contracture compared to those who underwent percutaneous needle aponeurotomy. The authors also noted a higher incidence of adverse events after injection therapy compared to percutaneous needle aponeurotomy, although the incidence of adverse events compared to open fasciectomy was not investigated. The effectiveness in restoring the functional capabilities of the hand was approximately the same for all methods. Similar findings were obtained in a more recent meta-analysis by D. Obed *et al.* [15]. They also indicated a higher incidence of complications after the use of *Clostridium histolyticum* collagenase preparations compared to percutaneous needle aponeurotomy, although they did not investigate this in comparison with open fasciectomy. Among the side effects of treatment, local pain and swelling at the site of intervention were most often noted. Such symptoms were also noted in the study under review, but they did not pose a serious problem for patients, as they were short-lived and mild, especially in comparison with open fasciectomy, which is much more traumatic than percutaneous needle aponeurotomy.

Only two meta-analyses directly compared open fasciectomy and injection therapy with *Clostridium histolyticum* collagenase preparations. T.B. Cooper *et al.* [16] analysed 17 scientific publications that included 2142 joints in 1784 patients. The researchers concluded that both methods are equally effective. However, surgical treatment is accompanied by a significantly higher risk of complications, although it is associated with a lower likelihood of contracture recurrence.

R. Liechti *et al.* [17] analysing the results of 11 studies involving 1051 patients, also noted a higher likelihood of recurrence of Dupuytren's contracture after injection therapy compared to open fasciectomy. According to their results, the use of *Clostridium histolyticum* collagenase preparations increase the likelihood of contracture recurrence by 5 times compared to invasive intervention. Despite this, the data of R. Liechti *et al.* [17] indicate that the clinical efficacy of open fasciectomy is superior to injection therapy, although the data of the current study do not support this opinion.

A high relapse rate after injection therapy has been found in other studies. According to the results of the meta-analysis A.B. Sandler *et al.* [12], the probability of recurrence of Dupuytren's contracture within the next two years after injection therapy is about 23%. M. Brazzelli *et al.* [11] note that eight years after the use of *Clostridium histolyticum* collagenase preparations, recurrence is observed in 100% of cases. According to S. Nann *et al.* [18], the highest probability of contracture recurrence is observed between

2 and 5 years after the intervention. In this study, it was not possible to assess the recurrence rate due to the short follow-up period. However, the information on complications is consistent with the observations obtained in this study.

In terms of financial costs, therapy with *Clostridium histolyticum* collagenase preparations is more cost-effective than open fasciectomy, as highlighted by the findings of A.V. Fitzpatrick *et al.* [19]. The researchers acknowledge that in the case of severe contracture with severe functional impairment, invasive intervention is still a rational choice rather than injection therapy. On the other hand, M. Brazzelli *et al.* [11] believe that for patients with moderate functional impairment, injection therapy with *Clostridium histolyticum* collagenase preparations is both clinically and economically feasible.

A meta-analysis conducted by C.R. Wong *et al.* [20] investigated the treatment of recurrent Dupuytren's contracture. The researchers analysed 12 studies involving 311 patients who had undergone various treatments, such as percutaneous needle aponeurotomy, injections of *Clostridium histolyticum* collagenase drugs, fasciotomy or fasciectomy, and suffered from recurrent contracture formation. The study showed that none of these approaches is effective enough to treat recurrent Dupuytren's contracture. Therefore, given that none of the existing methods are ideal for preventing recurrence, it is important to find a treatment that minimises the likelihood of contracture recurrence. Currently, open fasciectomy is considered the most effective in preventing recurrence, but it has its drawbacks. Therefore, stratifying patients according to the risk of Dupuytren's contracture recurrence is a logical approach. Patients with a low risk of recurrence may be offered injection therapy, while patients with a high risk should be recommended for surgery.

The causes and risk factors for recurrence in patients with Dupuytren's contracture are not yet well understood. In 2018, an article by S. Hindocha [21] described the diathesis of Dupuytren's disease. Scientists have identified several phenotypic features that are associated with a more severe course of the disease, its faster development, and a higher likelihood of relapse after treatment. Among these features were a burdened family history, bilateral lesions, ectopic manifestations of Dupuytren's contracture, onset of pathology at the age of less than 50 years, and male gender. L. Geoghegan *et al.* [22] conducted a large meta-analysis that analysed 51 studies with a total of 54 491 patients. They confirmed that these phenotypic features are indeed associated with an increased risk of disease recurrence, although they do not affect the severity of the disease. Clinicians should consider these risk factors when providing patients with recommendations for the treatment of Dupuytren's contracture.

Conclusions

The study found that the treatment of Dupuytren's contracture with *Clostridium histolyticum* collagenase preparations is no less effective than open fasciectomy. The study demonstrated that even in cases where it is not possible to break the

fibrous cord after the first injection, the probability of clinically successful treatment with the second and third injections is high. According to the study, recovery after the use of *Clostridium histolyticum* collagenase preparations is much faster than after open fasciectomy. Patients do not need rehabilitation and do not lose their ability to work, which is especially important for young and middle-aged patients. In terms of cost-effectiveness, injection treatment is also superior to surgery, except in cases of severe Dupuytren's contracture, which was not the subject of this study. The study showed that after injection therapy, patients are significantly more satisfied than those who underwent surgery.

Since injection therapy involves a certain amount of tissue trauma caused by the rupture of the fibrous cord, pain and swelling of the hand are inevitable. However, the study confirmed that the duration of these symptoms is limited to a few days, and their severity is much less compared to pain and swelling after a full-fledged surgical intervention, such as open fasciectomy. According to the study, prolonged wound healing and cosmetic defects that occur after open fasciectomy are significant disadvantages

of surgical treatment. A significant disadvantage of injection therapy is the higher recurrence rate of Dupuytren's contracture compared to open fasciectomy surgery. The highest risk of contracture recurrence is between two and five years after treatment. These data somewhat limit the possibilities of widespread use of *Clostridium histolyticum* collagenase preparations.

A promising area for further research is the identification of risk factors for the recurrence of Dupuytren's contracture. Preliminary data indicate that patients without a family history of contractures, with the onset of the disease in old age and with unilateral lesions have a lower risk of recurrence. In addition, it is necessary to find methods to prevent recurrence of Dupuytren's contracture after treatment.

Acknowledgements

None.

Conflict of Interest

The author declares no conflict of interest.

References

- [1] Salari N, Heydari M, Hassanabadi M, Kazeminia M, Farshchian N, Niaparast M, et al. The worldwide prevalence of the Dupuytren disease: A comprehensive systematic review and meta-analysis. *J Orthop Surg Res*. 2020;15:495. DOI: [10.1186/s13018-020-01999-7](https://doi.org/10.1186/s13018-020-01999-7)
- [2] Layton T, Nanchahal J. Recent advances in the understanding of Dupuytren's disease. *F1000Res*. 2019;8:231. DOI: [10.12688/f1000research.17779.1](https://doi.org/10.12688/f1000research.17779.1)
- [3] Ruettermann M, Hermann RM, Khatib-Chahidi K, Werker PMN. Dupuytren's disease – etiology and treatment. *Dtsch Arztebl Int*. 2021;118(46):781–88. DOI: [10.3238/arztebl.m2021.0325](https://doi.org/10.3238/arztebl.m2021.0325)
- [4] Jovanovic NA, Smilic L, Smilic T, Markovic-Jovanovic SR, Mitic J, Filimonovic J, et al. Quality of metabolic control, serum potassium, and aging are the major determinants of severity of musculoskeletal disorders in hospitalized diabetic patients. *Int J Diabetes Dev Ctries*. 2020;40:296–2. DOI: [10.1007/s13410-019-00776-5](https://doi.org/10.1007/s13410-019-00776-5)
- [5] Murínová L, Perečinský S, Jančová A, Murín P, Legáth L. Is Dupuytren's disease an occupational illness? *Occup Med*. 2021;71(1):28–33. DOI: [10.1093/occmed/kqaa211](https://doi.org/10.1093/occmed/kqaa211)
- [6] Rydberg M, Zimmerman M, Persson Löfgren J, Gottsäter A, Nilsson PM, Melander O, Dahlin LB. Metabolic factors and the risk of Dupuytren's disease: Data from 30,000 individuals followed for over 20 years. *Sci Rep*. 2021;11:14669. DOI: [10.1038/s41598-021-94025-7](https://doi.org/10.1038/s41598-021-94025-7)
- [7] Wang Z, Wang Z, Yan Z, Xu Z, Gao A. Smoking, alcohol consumption and risk of Dupuytren's disease: A Mendelian randomization study. *BMC Med Genomics*. 2023;16:212. DOI: [10.1186/s12920-023-01650-4](https://doi.org/10.1186/s12920-023-01650-4)
- [8] Sanjuan-Cervero R. Current role of the collagenase *Clostridium histolyticum* in Dupuytren's disease treatment. *Ir J Med Sci*. 2020;189:529–34. DOI: [10.1007/s11845-019-02127-z](https://doi.org/10.1007/s11845-019-02127-z)
- [9] Dupuytren's contracture [Internet]. [cited 2023 Nov 23]. Available from: <https://bestpractice.bmj.com/topics/en-gb/983>
- [10] International ethical guidelines for health-related research involving humans [Internet]. Geneva: CIOMS; 2016 [cited 2023 Nov 23]. 122 p. Available from: <https://doi.org/10.56759/rgxl7405>
- [11] Brazzelli M, Cruickshank M, Tassie E, McNamee P, Robertson C, Elders A, et al. Collagenase *Clostridium histolyticum* for the treatment of Dupuytren's contracture: Systematic review and economic evaluation. *Health Technol Assess*. 2015;19(90). DOI: [10.3310/hta19900](https://doi.org/10.3310/hta19900)
- [12] Sandler AB, Scanaliato JP, Dennis T, Gonzalez-Trevizo GA, Raiciulescu S, Nesti L, Dunn JC. Treatment of Dupuytren's contracture with collagenase: A systematic review. *Hand*. 2022;17(5):815–24. DOI: [10.1177/1558944720974119](https://doi.org/10.1177/1558944720974119)
- [13] Sanjuan-Cerveró R, Carrera-Hueso FJ, Vazquez-Ferreiro P, Ramon-Barrios MA. Efficacy and adverse effects of collagenase use in the treatment of Dupuytren's disease: A meta-analysis. *Bone Joint J*. 2018;100-B(1):73–80. DOI: [10.1302/0301-620X.100B1.BJJ-2017-0463.R1](https://doi.org/10.1302/0301-620X.100B1.BJJ-2017-0463.R1)
- [14] Soreide E, Murad MH, Denbeigh JM, Lewallen EA, Dudakovic A, Nordsletten L, et al. Treatment of Dupuytren's contracture: A systematic review. *Bone Joint J*. 2018;100-B(9):1138–45. DOI: [10.1302/0301-620X.100B9.BJJ-2017-1194.R2](https://doi.org/10.1302/0301-620X.100B9.BJJ-2017-1194.R2)

- [15] Obed D, Salim M, Schlottmann F, Bingoel AS, Panayi AC, Dastagir K, et al. Short-term efficacy and adverse effects of collagenase clostridium histolyticum injections, percutaneous needle fasciotomy and limited fasciectomy in the treatment of Dupuytren's contracture: A network meta-analysis of randomized controlled trials. *BMC Musculoskelet Disord.* 2022;23(1):939. DOI: [10.1186/s12891-022-05894-6](https://doi.org/10.1186/s12891-022-05894-6)
- [16] Cooper TB, Poonit K, Yao C, Jin Z, Zheng J, Yan H. The efficacies and limitations of fasciectomy and collagenase clostridium histolyticum in Dupuytren's contracture management: A meta-analysis. *J Orthop Surg.* 2020;28(2):2309499020921747. DOI: [10.1177/2309499020921747](https://doi.org/10.1177/2309499020921747)
- [17] Liechti R, Merky DN, Sutter D, Ipaktchi R, Vögelin E. Collagenase clostridium histolyticum injection versus limited fasciectomy for the treatment of Dupuytren's disease: A systematic review and meta-analysis of comparative studies. *Arch Orthop Trauma Surg.* 2023. DOI: [10.1007/s00402-023-05004-8](https://doi.org/10.1007/s00402-023-05004-8)
- [18] Nann S, Kovoor J, Fowler J, Kieu J, Gupta A, Hewitt J, et al. Surgical management of dupuytren disease: A systematic review and network meta-analyses. *Hand.* 2023;15589447231174175. DOI: [10.1177/15589447231174175](https://doi.org/10.1177/15589447231174175)
- [19] Fitzpatrick AV, Moltaji S, Ramji M, Martin S. Cost analyses of fasciectomy, needle aponeurotomy, and collagenase injection for treatment of dupuytren's contracture: A systematic review. *Plast Surg.* 2021;29(4):257–64. DOI: [10.1177/2292550320963111](https://doi.org/10.1177/2292550320963111)
- [20] Wong CR, Huynh MNQ, Fageeh R, McRae MC. Outcomes of management of recurrent dupuytren contracture: A systematic review and meta-analysis. *Hand.* 2022;17(6):1104–13. DOI: [10.1177/1558944721994220](https://doi.org/10.1177/1558944721994220)
- [21] Hindocha S. Risk factors, disease associations, and dupuytren diathesis. *Hand Clin.* 2018;34(3):307–14. DOI: [10.1016/j.hcl.2018.03.002](https://doi.org/10.1016/j.hcl.2018.03.002)
- [22] Geoghegan L, Man J, Jain A, Price A, Gibbons E, Jerosch-Herold C, et al. Factors associated with the development, progression, and outcome of dupuytren disease treatment: A systematic review. *Plast Reconstr Surg.* 2021;148(5):753–63. DOI: [10.1097/PRS.00000000000008420](https://doi.org/10.1097/PRS.00000000000008420)

Контрактура Дюпюїтрена, що лікується колагеназою *Clostridium histolyticum*

Мартіна Відова Угурбаш

Доктор медицини, доцент

Університет Павла Йозефа Шафарика в Кошице

041 80, вул. Шробарова, 2, м. Кошице, Словацька Республіка

<https://orcid.org/0000-0003-4620-6031>

Анотація. Лікування контрактури Дюпюїтрена покращує якість життя пацієнтів, але стандартна відкрита фасціектомія є травматичною і вимагає тривалої реабілітації. Метою дослідження було визначити ефективність ін'єкційного лікування препаратами колагенази порівняно з відкритою фасціектомією. Обстежено сорок пацієнтів. З них 15 лікували препаратами колагенази *Clostridium histolyticum* (основна група), а 25 піддалися обмеженій фасціектомії (контрольна група). У 11 (73,3 %) хворих основної групи відновлення рухливості уражених суглобів досягнуто після першої ін'єкції, у 3 (20 %) – після другої і в 1 (6,7 %) – після третьої ін'єкції. Пацієнти основної групи залишалися працездатними після лікування і не потребували реабілітації; на день втручання функція верхньої кінцівки повністю відновилася. Сухість шкіри в місці втручання за період спостереження турбувала 12 (80 %) пацієнтів основної групи, свербіж та зміна кольору шкіри в місці втручання – 5 (33,3 %). У 25 (100 %) хворих контрольної групи повністю відновилися рухливості суглобів. Можливість користуватися рукою після операції у пацієнтів контрольної групи була обмежена протягом 6 (4,5; 10) днів. Усі пацієнти контрольної групи потребували реабілітації для зняття скутості та відновлення функціональних можливостей кисті. Термін непрацездатності у цих пацієнтів тривав 16 (12; 24,5) діб. 11 (44 %) пацієнтів під час спостереження скаржилися на біль або дискомфорт у ділянці втручання, 24 (96 %) пацієнтів турбував свербіж. Задоволеність вибором методу лікування в основній групі була більшою, ніж у контрольній. Рецидивів за період спостереження в обох групах не було. Таким чином, ефективність препаратів колагенази *Clostridium histolyticum* порівнянна з результатами хірургічного лікування. Малоінвазивне лікування оптимально для пацієнтів з легким перебігом захворювання, а також для тих, у кого низький ризик рецидиву контрактури. Результати цього дослідження можуть бути корисними хірургам при виборі оптимального методу лікування контрактури Дюпюїтрена

Ключові слова: долонний фіброматоз; малоінвазивне втручання; хірургія кисті; відкрита фасціектомія; клінічне дослідження; ведення пацієнтів