

Effect of pelvic tilt on changing the centre of rotation of the hip joint in preoperative planning

Oleksandr Zubkov*

Postgraduate Student

Institute of Traumatology and Orthopedics of the National Academy of Medical Sciences of Ukraine

01601, 27 Bulvarno-Kudriavska Str., Kyiv, Ukraine

<https://orcid.org/0009-0002-6763-5062>

Victor Torchynskyi

Doctor of Medical Sciences, Senior Researcher

Institute of Traumatology and Orthopedics of the National Academy of Medical Sciences of Ukraine

01601, 27 Bulvarno-Kudriavska Str., Kyiv, Ukraine

<https://orcid.org/0000-0003-4818-9511>

Abstract. The growing number of hip replacements associated with an ageing population requires more accurate and efficient methods of planning operations to ensure the success of interventions and minimise the risk of complications. The study aimed to demonstrate how changes in the pelvic angle affect the accurate determination of the centre of rotation of the hip joint. The study used dry pelvic and femoral bones with a 4 mm diameter implanted steel ball in the femoral head for modelling. X-rays were taken using a PLX 140 X-ray machine to record the displacement of the centre of rotation. The study confirmed the hypothesis that a change in the pelvic angle leads to a shift in the centre of rotation of the hip joint. This displacement requires attention during preoperative planning, as it can affect the choice and placement of the endoprosthesis. The study found that a high pelvic angle makes it difficult to fit a hip prosthesis, increasing the risk of prosthesis wear and dislocation. This requires an individualised approach to each patient, the use of special implants and postoperative monitoring. It is necessary to assess the anteversion and inclusion of the prosthesis, adjust the implantation depth and select the appropriate types of prosthesis based on the patient's anatomy. The use of 3D modelling helps to optimise the placement of the prosthesis. Addressing anatomical features is key to reducing the risk of complications and improving the long-term results of arthroplasty

Keywords: arthroplasty; anatomical parameters; population ageing; quality of treatment; long-term results; optimisation of surgery; risk of complications

✦ INTRODUCTION

The issue of optimisation of preoperative planning for total hip arthroplasty (THA) has gained importance in modern orthopaedic surgery. Preoperative planning plays a critical role in determining the surgical strategy, choosing a prosthesis and establishing its optimal placement to achieve the best functional results and reduce the risk of postoperative complications. One of the key aspects that affect the success of THA is the accurate determination of the centre of rotation of the hip joint. The scientific community is increasingly recognising that the patient's anatomical parameters, in particular the pelvic angle, have a

significant impact on the determination of this centre of rotation, which in turn affects the overall surgical outcome.

A study by L. Yao *et al.* [1] determined that older patients who underwent hip or knee arthroplasty in the first six months after surgery reported functional limitations resulting from hip or knee-related symptoms. This study adds to the understanding of the factors that influence perceptions of participation among older patients undergoing hip or knee arthroplasty.

Similar clinical trials have been conducted in Ukraine, which may have an impact on the understanding of

Suggested Citation:

Zubkov O, Torchynskyi V. Effect of pelvic tilt on changing the centre of rotation of the hip joint in preoperative planning. Bull Med Biol Res. 2024;6(1):24–33. DOI: 10.61751/bmbr/1.2024.24

*Corresponding author



scientists about the importance of determining the pelvic angle before planning hip or knee prosthetics. The study by I. Zazirnyi [2] confirmed the safety and cost-effectiveness of THA, demonstrating significant progress in the development of less invasive surgical techniques, improvement of materials and technologies, which contributes to tissue preservation, implant durability, biocompatibility and ability to integrate with bone tissue. However, challenges such as the risk of infections and dislocations require additional research and improved clinical practices. The researcher draws attention to the importance of thoroughly testing innovations and monitoring their application, as well as the need to address biomechanical aspects, in particular the angle of the pelvis, to optimise the positioning of the prosthesis after THA. These findings may be related to pelvic tilt angle and hip prosthetics, as optimising posture and balance through rehabilitation can improve load distribution on the prosthetic joint, reducing the risk of complications and promoting better implant adaptation [3].

Additionally, studies have shown a close relationship between anatomical and biomechanical characteristics, such as pelvic tilt angle, and the occurrence of complications after arthroplasty. Optimisation of the positioning of the endoprosthesis, considering the individual characteristics of the patient, is critical to reducing the risk of instability, dislocation and other complications, ensuring the long-term functioning of the implant and improving the quality of life of patients [4, 5]. Thus, the integration of advanced surgical techniques, considering the anatomical features of each patient, is key to successful recovery and ensuring optimal long-term results of arthroplasty treatment [6].

Despite the existing results, there have not been enough studies conducted in this area. The main objective of the study was to prove that a change in the pelvic tilt angle affects the determination of the centre of rotation of the hip joint, which is critical in the preoperative planning of THA. This knowledge is necessary for accurate positioning of the prosthesis, minimising the risk of post-operative complications and ensuring better long-term treatment results.

★ MATERIALS AND METHODS

The study was conducted at the Institute of Traumatology and Orthopedics of the National Academy of Medical Sciences of Ukraine from January 2023 to January 2024. In this study, the main materials were dry pelvic and femoral bones, into which a 4 mm diameter steel ball was implanted in the femoral head to simulate a change in the centre of rotation. The bones had no pathologies or signs of chronic diseases that could affect the results of the study.

As for the balloon implantation technique, they were made of a special medical alloy that meets all quality standards and has a standard diameter of 4 mm. The balls were placed in the femoral head in a place that corresponds exactly to the area of the centre of rotation of the joint. This was done to accurately reproduce the physiological movement of the joint during the experiment. The ball was surgically fixed in the head of the femur. This process ensured that the ball was securely fixed in the correct position for the subsequent experiment. This method of ball implantation was used to accurately reproduce the conditions of joint movement and obtain reliable results of the study.

To obtain X-rays of the pelvis and femur with the implanted balloon, the patient bones were carefully positioned on the X-ray table in the desired position. The bones must be properly aligned to obtain high-quality images. The X-ray tube, which emits X-rays, was positioned according to the required geometry and angle to optimally visualise the pelvic and femoral bones. The obtained X-rays were processed using appropriate software to improve image quality and clarity. The images were analysed in detail to determine the exact centre of joint rotation. This measurement was carried out using specialised length and angle measurement software, which ensured high accuracy of the results. This innovative approach made it possible to visualise and measure the displacement of the centre of rotation with high accuracy using X-rays taken with the PLX 140 apparatus (USA). The device has a high X-ray power for high-quality images and the ability to adjust the position and orientation of the X-ray tube for precise positioning and obtaining the required images. The device can operate in a wide range of energies and frequencies, which allows it to be used for a variety of clinical applications. Built-in algorithms can be used to process the images captured, providing clear and detailed images. The technique was based on the implantation of a steel ball into the femoral head, which was performed to create a visual marker system for accurate tracking of the dynamics of the joint's centre of rotation during changes in the pelvic angle.

The PLX 140 X-ray machine played a critical role in the research study, as it was used to accurately determine the initial position of the centre of rotation of the hip joint and to document the changes caused by the modification of the pelvic angle. This stage of the study was particularly significant because it provided the ability to visualise and quantify the displacement of the centre of rotation resulting from changes in pelvic position. The use of an X-ray machine was used to obtain clear and detailed images, which are critical for accurate analysis of the biomechanical parameters of the hip joint. This approach not only improved the accuracy of the study but also opened new perspectives for understanding the relationship between the anatomical structure of the pelvis and the functional state of the hip joint, which is crucial for optimising preoperative planning and increasing the effectiveness of total hip replacement.

Modelling changes in the pelvic tilt angle was a key element of the study aimed at analysing the impact of pelvic anatomical variations on the position of the centre of rotation of the hip joint, which is crucial for the success of total joint replacement. As part of this experiment, a technique was used that allowed for precise and controlled changes in the angle of the pelvis from its natural position to angular deviations of 0, 10, 20, 30 and 40°. This systematic change in angles was implemented using specially designed setups and techniques that ensured high accuracy and reproducibility of the study conditions. To simulate changes in the angle of the pelvis, special devices were used to reproduce this change realistically. For fixing the bones, the machines were equipped with special fixators or holders that ensured stable fixation of the bones during the simulation. The components of the plants were made of strong and reliable materials such as plastic to ensure high stability and durability. The bones were fixed in a certain position employing fixators. By adjusting the angle of the pelvis with the help

of the devices, the change under study was reproduced. During the simulation, the position of the bones was measured and monitored to ensure that the change in pelvic angle was accurately reproduced.

In the context of the study, which revealed difficulties with hip prosthesis placement due to the high pelvic angle, the use of specially designed devices and techniques is key to optimising the arthroplasty procedure and minimising risks: 3D modelling and planning, navigation systems during operations using computer navigation or robotic systems. This detailed modelling allowed for an in-depth analysis of the biomechanical shifts in the position of the centre of rotation that occur as a result of changes in the pelvic angle. As part of the research, a comprehensive analysis was conducted of the impact of changes in the pelvic tilt angle on the position of the centre of rotation of the hip joint, which is essential for optimising preoperative planning for THA. For this purpose, specialised materials were prepared, including the collection of dry pelvic and femoral bones and the implantation of a steel ball into them. The method of modelling changes in the pelvic angle and recording the corresponding changes in the position of the centre of rotation on X-rays made it possible to conduct a detailed analysis of biomechanical changes in the hip joint. The application of this technique has opened the possibility of identifying critical angular deviations at which the displacement of the centre of rotation reaches such values that can significantly affect the mechanics of the hip joint and the efficiency of the endoprosthesis.

For the statistical analysis of the data in this study, specialised software was used to analyse medical images and measure the parameters of X-ray images. This software was able to accurately measure the displacements of the centre of rotation of the hip joint, which allowed for a highly accurate analysis of the effect of changes in the pelvic angle on the anatomical position and functionality of the hip joint. In addition, this software was used to identify subtle biomechanical changes associated with pelvic tilt modification and their potential impact on the choice of location and orientation of the hip replacement. Medical image processing software such as OsiriX (France) and ImageJ (USA) were used. These applications provide extensive capabilities for analysing and measuring X-ray image parameters, including a variety of statistical methods for processing the data.

All experimental procedures were carried out following the ethical principles established by the institution that conducted the study. Relevant ethical documents and standards that were addressed during the research include the Declaration of Helsinki [7], Belmont Report [8]. Additionally, the Guideline for Good Clinical Practice E6(R1) [9], Ethical Principles of Psychologists and Code of Conduct [10], and Data protection in the EU [11] were also considered.

★ RESULTS

The angle of the pelvis has a significant impact on the positioning of the hip prosthesis and its functionality after fitting. This is because the pelvic tilt angle determines the position of the acetabular component, which should be optimally oriented for normal hip biomechanics. Incorrect positioning of this component can lead to increased pressure on the prosthesis, which can cause wear, deformation

or even destruction. If the pelvic angle is too high or too low, this can lead to an incorrect distribution of the load on the hip joint, which in turn increases the risk of prosthesis dislocation, pain and limited mobility. It can also cause changes in the patient's gait and increase the risk of falls and injuries. Concerning the correlation between pelvic angle and the fitting process, the pelvic angle must be accurately considered when planning and fitting the acetabular component to achieve optimal prosthetic results. The angle of anteversion and lateral deviation should be carefully measured and considered to minimise the risk of the above complications. Modern technologies, such as computed tomography and computer modelling, allow surgeons to predict and plan interventions based on the individual characteristics of each patient. This approach optimised surgical outcomes and provided patients with a better quality of life after surgery.

In the context of this scientific experiment, an advanced technique was used to accurately and controllably modify the pelvic angle at intervals of 0, 10, 20, 30 and 40° from its baseline position. These angular changes were made using innovative devices and procedures designed to ensure precision and repeatability of the experimental conditions. This careful modelling approach allowed for a comprehensive analysis of the biomechanical displacements of the centre of rotation that occur in response to changes in pelvic angle. The use of this methodology was used to determine those critical angular parameters, upon reaching which the shift of the centre of rotation becomes so significant that it can affect the overall mechanics of the hip joint and the optimal functioning of the endoprosthesis. The image shows a pelvic model representing the natural position with a pelvic angle of 0° (Fig. 1). This is a standard starting position for modelling and determining the basic parameters of preoperative planning for hip arthroplasty.

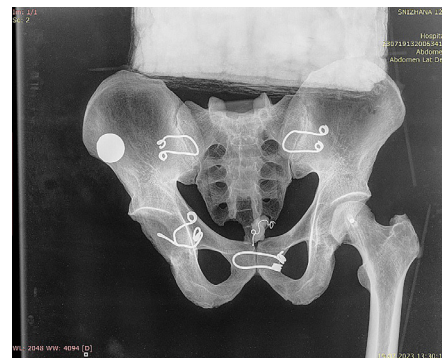


Figure 1. Simulate a 0° pelvic tilt angle
Source: compiled by the authors

X-ray markers visible on the femur are used to accurately assess the position of the centre of rotation. This image can be used to measure the pelvic tilt angle, which is important for analysing the potential impact of pelvic tilt on the long-term functionality and stability of the prosthesis. In this case, the zero pelvic tilt angle allows to definition of the “ideal” starting point from which additional measurements will be taken when the tilt is changed to higher angles, allowing for assessment changes in the position of the centre of rotation and deviation from the

optimal position of the prosthesis. The image has a clear view of the pelvis and femur, which can be used to identify anatomical features and potential areas for attention when planning prosthetics. Such a detailed analysis of bone structures in the context of preoperative planning is critical for successful hip arthroplasty.

Figure 2 shows an X-ray of an anatomical model of the pelvis simulating a horizontal orientation with a pelvic angle of 10° . This image serves as a starting point for the analysis of preoperative planning of hip arthroplasty and assessment of the basic parameters for the implantation of the prosthesis.

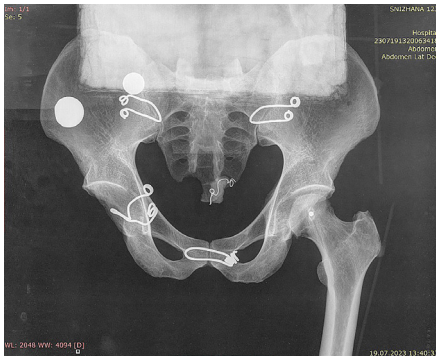


Figure 2. Simulate a 10° pelvic tilt angle

Source: compiled by the authors

The pelvic tilt angle of 10° creates the conditions for further measurements to assess the effect of different tilt angles on the centre of rotation of the joint and to identify abnormalities in the positioning of the endoprosthesis. The marked clarity of the visualisation of bone structures in the image allows you to examine the anatomical characteristics in detail and choose the optimal implantation strategy. Such a thorough analysis of the bone matrix plays a key role in preoperative planning, creating the basis for effective hip arthroplasty and ensuring the best clinical outcomes. In the X-ray, the pelvic angle was modified to 20° from the horizontal position, demonstrating the effect of the change in inclination on the positioning of the arthroplasty (Fig. 3).

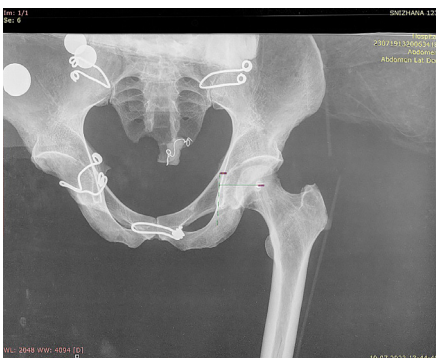


Figure 3. Simulate a 20° pelvic tilt angle

Source: compiled by the authors

This image has practical implications for preoperative planning, allowing orthopaedic surgeons to understand how changes in pelvic angle can affect optimal implant

placement (Fig. 3). The image shows that at an angle of inclination of 20° , changes occur that can potentially affect the biomechanics of the hip joint and determine the strategy for implant placement. The markers on the image can be used to measure the angular deviation and assess its impact on the position of the joint's centre of rotation. This data is critical for preventing complications such as implant wear or joint instability after surgery.

The X-ray image shows the pelvic skeleton with implanted metal structures with the pelvis tilted by 30° (Fig. 4). This deviation is performed to study biomechanical changes in the position of the implants and their orientation relative to the pelvic and femoral bones, which is important for preoperative planning.

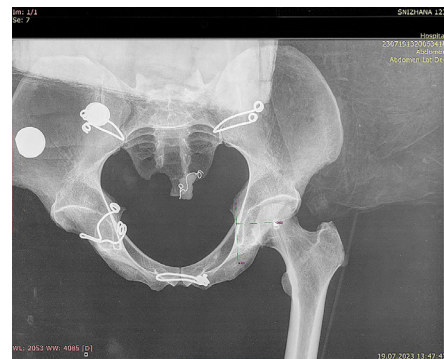


Figure 4. Simulate a 30° pelvic tilt angle

Source: compiled by the authors

A 30° shift in pelvic angle shows how a change in pelvic position can affect the angle of inclination, which then affects the functionality and service life of the prosthesis. This image provides valuable information for surgeons and engineers involved in biomechanics and implant design, allowing them to better understand the impact of anatomical deviations on optimal prosthetic positioning. The image can also be useful for developing personalised surgical plans, considering individual anatomical variations in patients.

The X-ray in Figure 5 shows a pelvic model used for scientific research with implanted markers that simulate a 40° change in pelvic angle. This image is intended to simulate physiological conditions to evaluate the effect of tilt angle on surgical planning for hip arthroplasty.

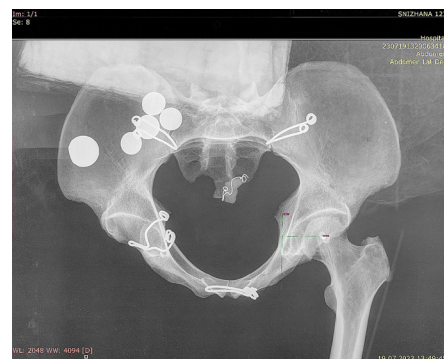


Figure 5. Simulate a 40° pelvic tilt angle

Source: compiled by the authors

Markers placed on the bone model are highlighted in bright white, indicating the use of a material with a high degree of radiopaque contrast. The image shows the anatomical structures of the pelvis and femur with metal markers on them. These markers accurately determine the position and orientation relative to the bones. The image illustrates a carefully planned placement of markers that can reproduce the corresponding angular changes in the position of the pelvic bones, which is important for preoperative modelling. It shows not only the bones themselves but also the spatial relationships between them, which is critical for planning the exact location of the endoprosthesis, its inclination and orientation, as well as for predicting changes in the load on the joint after surgery. This approach demonstrates the importance of advanced imaging techniques for optimising surgical strategy and may contribute to the development of more accurate algorithms for preoperative planning, risk reduction and improved patient care in orthopaedic surgery.

Based on the analysis of the data obtained, the study found that a change in the pelvic tilt angle significantly affects the location of the centre of rotation of the hip joint, which, in turn, has significant implications for the choice of optimal placement of the endoprosthesis and prevention of possible postoperative complications. The strategy for hip prosthetics at zero pelvic tilt and 40° tilt will be significantly different due to changes in anatomy and biomechanics that require a different approach to prosthesis planning and fitting. For example, at 0° of pelvic tilt, the prosthesis can be planned based on standard anatomy without the need for correction for significant anterior or posterior pelvic tilt. The angle of anteversion and inclusion of the acetabular component can be set closer to the “ideal” standard values, which are considered optimal for most patients. The general orientation of the implants concerning the bone structures is standard, which facilitates placement and ensures good functional results. At 40° of pelvic tilt, specialised planning is required to address the increased pelvic tilt, which can affect the positioning of the acetabular component and the need for correction to prevent excessive soft tissue tension or strain. It may be necessary to adjust the angle of implantation of the acetabular component to avoid improper loading of the prosthesis and reduce the risk of dislocation. Computer navigation and computer modelling become even more critical for the precise positioning of the implants concerning the abnormal pelvic position.

In general, the greater the pelvic angle, the more difficult it is to ensure the correct positioning of the acetabular component of the prosthesis and the greater the risks associated with improper load distribution, prosthesis wear and dislocations. This requires a more individualised approach to each patient and may require the use of non-standard implants or implantation techniques, as well as more thorough postoperative monitoring and rehabilitation. Fitting a hip prosthesis is a complex process that requires considering many individual anatomical features of the patient, including the angle of the pelvis. Depending on this angle, the prosthesis placement strategy may need to be adjusted. Assessment and correction of anteversion and inclusion of the denture cup should be performed. Anteversion is the angle at which the cup is placed in the acetabular bed. An

incorrect angle of anteversion can cause an increase or decrease in soft tissue tension around the prosthesis and affect the risk of dislocation. Furthermore, the depth of implantation of the acetabular component is adjusted and should consider changes in the anatomy that occur at different pelvic angles. This ensures that the load is evenly distributed over the prosthesis. Depending on the patient's anatomy and pelvic angle, it may be necessary to select specific types or models of prosthesis to optimise fit and functionality. With the help of 3D modelling and preoperative planning, it is possible to determine exactly how the pelvic angle will affect the position of the prosthesis and what adjustments need to be made for optimal positioning. Post-operative rehabilitation programmes should be adapted to the changes in biomechanics resulting from pelvic tilt to promote proper recovery and reduce the risk of complications. Taking these factors into account is important to ensure the long-term success of the prosthesis and reduce the risk of complications such as pain, limitation of movement, inappropriate loading and dislocation of the prosthesis.

The results of the study emphasise the importance of considering the individual anatomical features of the patient in the preoperative planning of THA. A detailed understanding of the relationship between the pelvic tilt angle and the position of the joint's centre of rotation allows for optimised surgical technique, maximised prosthesis functionality, and improved long-term treatment outcomes. Thus, the study makes an important contribution to the development of preoperative planning in orthopaedic surgery, providing a foundation for further scientific developments in this area.

★ DISCUSSION

The angle of the pelvis is a critical parameter that affects the biomechanics of the hip joint and its loading. Incorrect determination of this angle can lead to a shift in the centre of rotation of the joint, which in turn increases the risk of dislocation of the prosthesis, worsens functional outcomes, and may require revision surgery. The study used modern techniques, such as X-rays with modelling of the displacement of the centre of rotation, which allow for high accuracy in determining the angle of pelvic tilt and its impact on the position of the endoprosthesis.

The fact revealed in this study is that the pelvic tilt plays a significant role in the planning and fitting of hip arthroplasties, as it directly affects the functional anteversion and tilt of the acetabular component of the prosthesis. This understanding requires surgeons to take an individual approach to each case, based on a detailed analysis of the patient's anatomical features. These findings are echoed in the studies of such scholars as L. Yao *et al.* [1], J.D. Maratt *et al.* [12], Y. Kokubu *et al.* [13], who also studied the effect of pelvic tilt angle on the placement and functionality of hip arthroplasties. Their work emphasises the need to adapt the surgical strategy to this anatomical feature to improve the success of arthroplasty. The differences between studies are in the ways of assessing the effect of pelvic tilt and the methods of correcting the position of the acetabular component. While some researchers focus on the use of preoperative computed tomography or magnetic resonance imaging to determine the optimal position of the prosthesis, others suggest the use of an intraoperative

navigation system to achieve maximum accuracy in component placement. However, both lines of research emphasise the critical importance of preoperative planning and adaptation of surgical techniques to the individual anatomical characteristics of the patient. This encourages further scientific developments in the field of orthopaedic surgery to improve methods of assessment and planning of arthroplasty that consider the angle of inclination of the pelvis. The difference in approaches between the studies indicates the potential for future innovations in the field of orthopaedics, including the development of universal protocols for the assessment and planning of arthroplasty that would provide individualised and effective treatment of patients based on a comprehensive analysis of the anatomical and functional characteristics of the hip joint.

The fact that an individualised analysis of the hip joint anatomy, particularly the pelvic angle, is important is the starting point for a discussion with the study by H.H. Yun *et al.* [14]. Studies have highlighted the critical role of pelvic tilt angle in hip arthroplasty, emphasising its impact on prosthesis positioning and its potential to minimise the risks associated with prosthesis wear and dislocation. However, the study by the researchers addressed in detail the dynamics of pelvic tilt and rotation before and after surgery using advanced imaging techniques such as computed tomography and standing X-rays. This concludes that significant changes in pelvic tilt and rotation, which could affect the position of the prosthesis, usually do not occur [15, 16]. This study also highlights that pelvic tilt is crucial for an accurate assessment of the anteversion of the prosthesis cup, whereas pelvic rotation has less of an impact on this parameter. It coincides with those studies recognise the importance of anatomical planning and emphasise the need for individualised approaches to each patient to achieve optimal surgical outcomes. At the same time, the study by H.H. Yun *et al.* [14] adds a level of analysis, demonstrating that the stability of pelvic tilt and rotation after surgery is an indicator of successful prosthesis positioning, regardless of initial anatomical variations. The difference between these studies is in the methodology for assessing changes in the anatomical position of the pelvis and its impact on the orientation of the prosthesis. The researchers focus on specific metrics measured directly before and after surgery, which establishes a direct link between the stability of pelvic angular parameters and the success of arthroplasty. Thus, although the main conclusion about the importance of the pelvic angle in arthroplasty planning is the same, the study by the researchers provides a more in-depth analysis of the interaction between pelvic anatomical parameters and prosthesis positioning, using thorough imaging techniques.

The key discovery, which emphasises the importance of individualised analysis of the hip joint anatomy, especially the pelvic angle, before THA, has a deep resonance with the study conducted by T. Tateiwa *et al.* [17]. The research goes beyond traditional approaches to surgical planning, emphasising the need for a thorough understanding of the patient's anatomy to reduce the risk of complications and optimise treatment outcomes. The researchers focused on postoperative changes in global spinal sagittal alignment after hip arthroplasty, identifying the key role of accurate spinal positioning in preventing potential complications.

Similarly, the finding in this study highlights the importance of precise planning of the positioning of the hip prosthesis, considering the angle of the pelvis. In both cases, precision in planning surgical interventions is a key element in improving the effectiveness of treatment and minimising risks for patients. However, in contrast to the study by the researchers, which focuses on postoperative spinal alignment and its changes, this study focuses on the effect of pelvic angle on the planning and placement of hip prostheses. This difference in emphasis allows us to consider these studies as complementary, as they highlight different aspects of surgical planning and indicate the importance of a comprehensive approach to hip and spine surgery.

Both studies make a significant contribution to the development of preoperative planning in orthopaedic surgery, emphasising the need for an individualised approach based on a detailed analysis of each patient's anatomy. This reinforces the idea that the success of a surgical intervention depends on preliminary preparation and the ability to adapt surgical techniques to the patient's unique physiological characteristics. The authors' study, as well as that of other researchers [18-20], found that an increased pelvic tilt angle complicates the implantation of a hip prosthesis, increasing the risk of wear and dislocation, requiring an individual approach and postoperative care. The importance of assessing anatomical parameters such as anteversion and inclusion of the prosthesis is emphasised to optimise prosthesis positioning and reduce the risk of complications [21]. On the other hand, the study by T. Tateiwa *et al.* [17] focuses on the analysis of changes in global sagittal spinal alignment after THA, indicating the key role of accurate spinal positioning in preventing degenerative changes in the lumbar spine. It focuses on the impact of changes in pelvic and spinal position on long-term treatment outcomes, especially in cases with certain anatomical features. Both studies acknowledge the importance of individual anatomical characteristics in surgical planning and treatment strategy, emphasising the need for detailed preoperative analysis and planning. The main difference lies in the focus of the research. The first focuses on the implantation of a hip prosthesis and the associated risks due to the anatomy of the pelvis, while the second study looks at the impact of THA on the sagittal alignment of the spine, paying attention to long-term changes in the spinal column that can affect the patient's overall condition.

The key finding of the study is the critical role of individualised analysis of the hip joint anatomy, especially the pelvic angle, in preoperative planning for total hip replacement. This understanding allows surgeons to plan prosthesis placement more accurately, which helps to reduce the risk of complications, increase implant functionality and improve long-term patient outcomes. This research is leading to improvements in preoperative planning, including the use of advanced imaging techniques such as 3D modelling and the development of new surgical instruments and navigation systems to optimise prosthesis placement based on each patient's unique anatomy. This finding correlates with the study conducted by A. Eslam Pour *et al.* [22], A. Palit *et al.* [23], also focused on the study of changes in pelvic tilt and their impact on the functioning of hip prostheses. Their findings indicate that changes

in pelvic tilt, even by less than 10° , can cause significant problems, including the risk of prosthesis dislocation, depending on the patient's movements. Their findings highlight the importance of adapting prosthesis design, especially prosthesis head dimensions and stem angles, to minimise the risk of dislocation or impingement associated with changes in pelvic tilt. Studies demonstrate the importance of preoperative analysis and planning based on the patient's anatomy to optimise the results of THA. At the same time, this paper expands the understanding of this issue, emphasising the need to integrate advanced imaging techniques and develop the latest surgical tools to individualise surgical interventions. This, in turn, highlights the need for further research and technology development in this area to ensure the most effective and safe treatments for patients in need of arthroplasty.

The fact revealed in the study, which emphasises the critical importance of individualised analysis of the hip joint anatomy, especially the pelvic angle, before performing total hip arthroplasty, resonates with the work of such scientists as M. Okamoto *et al.* [24], C. Foissey *et al.* [5], also emphasise the importance of adequate monitoring and adjustment of the pelvic angle to ensure optimal placement of the endoprosthesis cup. Both studies emphasise that improper positioning of the prosthesis can lead to significant postoperative complications, including dislocation, increased wear of the prosthesis, and, as a result, reduced functionality and the need for repeated surgical interventions. The overlap between these studies lies in the recognition that accurate preoperative planning that addresses the individual anatomy of the patient is fundamental to achieving optimal surgical results. Thus, changing the angle of the pelvis requires not only accurate diagnosis before surgery but may also require the use of specialised surgical techniques and instruments to adapt to these unique features. Research also points to the potential benefits of using advanced technologies, such as 3D modelling and navigation systems, to improve the accuracy of endoprosthesis placement. However, the study by M. Okamoto *et al.* [24] has a specific focus on patients with low body mass index and a large range of internal rotation, which is important for identifying subgroups of patients at higher risk of pelvic tilt change. This emphasises the importance of not only universal approaches to planning and performing arthroplasty but also the need for a more detailed consideration of individual risk factors. Taking these addresses, it is possible to conclude that the integration of data from different studies contributes to the improvement of orthopaedic surgery practice, increasing the chances of successful intervention and minimising the risk of complications, which is an important contribution to the development of personalised medicine.

The fact that individualised analysis of the hip joint anatomy, particularly the pelvic angle, is important for planning THA is an important contribution to the practice of orthopaedic surgery. This insight allows surgeons to more accurately position the prosthesis, reducing the risk of complications, and improving implant functionality and overall patient outcomes. The development of preoperative planning methods, including the use of 3D modelling, creates prospects for further progress in orthopaedic

surgery and the development of personalised medicine. A study by H. Choe *et al.* [25], which indicates that repeated hip surgeries cause external rotation of the hip and increase the risk of collision and dislocation, especially in two-stage operations with muscle atrophy, demonstrates the importance of attention to anatomical details and potential changes after surgery. This study points to the difficulties that can arise due to anatomical changes after surgery and highlights the need to adapt surgical planning and postoperative care to minimise risks. Although studies have focused on anatomical features and their impact on surgical outcomes, the key discovery about the importance of pelvic tilt angle in planning for arthroplasty is complemented by the findings on the consequences of reoperation identified in the study by the researchers. Together, these studies highlight a comprehensive approach to hip surgery that requires a detailed understanding of the anatomy and potential joint changes to ensure the best possible treatment outcomes. The difference between the two is the emphasis on primary planning versus the complexities associated with re-operations, but they share a common commitment to minimising risks and improving patient outcomes by considering unique anatomical features.

Based on the studies presented, it is possible to conclude that pelvic tilt is a key parameter that has a significant impact on the success of total hip arthroplasty. Incorrect determination of this angle can lead to a shift in the centre of rotation of the joint, increasing the risk of dislocation of the prosthesis and the need for revision surgery. Modern imaging techniques, such as X-rays and computer modelling, allow for high accuracy in measuring the pelvic tilt and adapting the surgical approach to the individual anatomical features of the patient, which helps to optimise treatment outcomes and minimise the risk of complications. The interaction between the hip and the spine presents interesting challenges for the arthroplasty surgeon, requiring an in-depth assessment of both the coronal and sagittal planes during the planning of the operation. Understanding of this topic has improved significantly in recent years, but many questions remain. Well-designed prospective studies are needed to help identify and define how to integrate the sagittal plane into preoperative planning to determine optimal orientation to improve patient outcomes and load behaviour; only then can the benefits associated with the use of navigation/robotics reach their maximum potential, according to A. Premkumar *et al.* [26], G. Grammatopoulos *et al.* [27]. In comparison, the study by D. Kobayashi *et al.* [28] found an association between hip rotation and overall body alignment in patients undergoing THA. The authors emphasise the importance of considering hip rotation when planning and performing hip surgery to ensure optimal recovery. The study also noted that the interaction between the hip and spine poses a challenge to orthopaedic surgeons, requiring detailed planning of the operation, considering the coronal and sagittal planes. Despite significant progress in understanding this topic, there are still many unresolved issues that highlight the need for further research.

✦ CONCLUSIONS

When analysing the effect of changes in the pelvic tilt angle on the planning of hip arthroplasty, it should be

noted that this value is a key biomechanical parameter that affects the position and orientation of the acetabular component of the prosthesis.

As a result of the study using dry bone models with steel balls that simulate the centre of rotation of the femoral head, it became possible to measure and visualise the displacement of the centre of rotation with changes in the angle of inclination. During the experiment, using X-rays from the PLX 140, the displacement of the centre of rotation, which occurred when the pelvic angle was changed from 0 to 40°, was recorded. These studies have shown that with an increase in the pelvic tilt angle, there is a change in the position of the acetabular component of the prosthesis, which can lead to a change in the direction of loading on the prosthesis and the bone structures around it. This displacement can increase the risk of prosthesis dislocation, faster wear and other complications. Therefore, at 0° of pelvic tilt, preoperative planning can be based on standard anatomical landmarks and parameters, taking the typical position of the joint and prosthesis as a basis. However, with a significant pelvic tilt of 40°, it is neces-

sary to consider the changed geometry of the pelvic bones, which requires adjustment of implant angles and, possibly, the choice of specialised prosthesis types that would better adapt to the changed biomechanics. In addition, the preoperative planning must also be individually adapted to the increased tilt angle to ensure optimal recovery and reduce the risk of complications.

The study results highlight the importance of an individual approach to each arthroplasty case, where preoperative planning should be closely linked to the patient's precise anatomy and biomechanics. Therefore, it is possible to conclude that the range of pelvic tilt angles that should be considered when planning total arthroplasty should be expanded and the methods for determining these angles should be improved.

✦ ACKNOWLEDGEMENTS

None.

✦ CONFLICT OF INTEREST

The authors declare no conflict of interest.

✦ REFERENCES

- [1] Yao L, Jia Q, Wu J, Chai Y, Gao C, Wang Y, Li K, et al. Assessing perceived participation among older adults total hip arthroplasty and total knee arthroplasty patients six months post-surgery: A cross-sectional study. *Front Public Health*. 2023;11:1282461. DOI: [10.3389/fpubh.2023.1282461](https://doi.org/10.3389/fpubh.2023.1282461)
- [2] Zazirnyi I. Total hip arthroplasty during last 25 years. *Trauma*. 2020;21(5):32–41. DOI: [10.22141/1608-1706.5.21.2020.217088](https://doi.org/10.22141/1608-1706.5.21.2020.217088)
- [3] Mairesse S, Chazard E, Giraudet G, Cosson M, Bartolo S. Complications and reoperation after pelvic organ prolapse, impact of hysterectomy, surgical approach and surgeon experience. *Int Urogynecol J*. 2020;31:1755–61. DOI: [10.1007/s00192-019-04210-6](https://doi.org/10.1007/s00192-019-04210-6)
- [4] Okamoto M, Kawasaki M, Okura T, Ochiai S, Yokoi H. Comparison of accuracy of cup position using portable navigation versus alignment guide in total hip arthroplasty in supine position. *Hip Int*. 2021;31(4):492–99. DOI: [10.1177/1120700020908788](https://doi.org/10.1177/1120700020908788)
- [5] Foissey C, Batailler C, Fary C, Luceri F, Servien E, Lustig S. Transitioning the total hip arthroplasty technique from posterior approach in lateral position to direct anterior approach in supine position – Risk factors for acetabular malpositioning and the learning curve. *Int Orthop*. 2020;44:1669–76. DOI: [10.1007/s00264-020-04583-0](https://doi.org/10.1007/s00264-020-04583-0)
- [6] Vigdorichik JM, Sharma AK, Dennis DA, Walter LR, Pierrepont JW, Shimmin AJ. The majority of total hip arthroplasty patients with a stiff spine do not have an instrumented fusion. *J Arthroplasty*. 2020;35(6):252–54. DOI: [10.1016/j.arth.2020.01.031](https://doi.org/10.1016/j.arth.2020.01.031)
- [7] The World Medical Association. Declaration of Helsinki: Ethical Principles for Medical Research Involving Human Subjects [Internet]. [cited 2024 Jan 10]. Available from: <https://www.wma.net/what-we-do/medical-ethics/declaration-of-helsinki/>
- [8] Belmont Report: Ethical Principles and Guidelines for the Protection of Human Subjects of Research [Internet]. [cited 2024 Jan 10]. Available from: <https://www.hhs.gov/ohrp/regulations-and-policy/belmont-report/index.html>
- [9] European Medicines Agency. ICH Topic E 6 (R1) Guideline for Good Clinical Practice [standard online]. 2002 [cited 2024 Jan 10]. CPMP/ICH/135/95. Available from: https://www.ema.europa.eu/en/documents/scientific-guideline/ich-e6-r1-guideline-good-clinical-practice_en.pdf
- [10] Ethical Principles of Psychologists and Code of Conduct [Internet]. [cited 2024 Jan 10]. Available from: <https://www.apa.org/ethics/code>
- [11] Data protection in the EU [Internet]. [cited 2024 Jan 10]. Available from: https://commission.europa.eu/law/law-topic/data-protection/data-protection-eu_en
- [12] Maratt JD, Esposito CI, McLawhorn AS, Jerabek SA, Padgett DE, Mayman DJ. Pelvic tilt in patients undergoing total hip arthroplasty: When does it matter? *J Arthroplasty*. 2015;30(3):387–91. DOI: [10.1016/j.arth.2014.10.014](https://doi.org/10.1016/j.arth.2014.10.014)
- [13] Kokubu Y, Kawahara S, Kitamura K, Hamai S, Motomura G, Ikemura S, et al. Evaluation of the anterior acetabular coverage with a false profile radiograph considering appropriate range of positioning. *Sci Rep*. 2023;13:8288. DOI: [10.1038/s41598-023-35514-9](https://doi.org/10.1038/s41598-023-35514-9)
- [14] Yun HH, Murphy WS, Ward DM, Zheng G, Hayden B, Murphy SB. Effect of pelvic tilt and rotation on cup orientation in standing anteroposterior radiographs. *HIP Int*. 2020;30(1):48–55. DOI: [10.1177/1120700019831665](https://doi.org/10.1177/1120700019831665)
- [15] Szymański JK, Starzec-Proserpio M, Bartosińska-Raczkiewicz D, Krawczyk A, Kukulski P, Jakiel G. Impact of preoperative pelvic floor muscle function on the success of surgical treatment of pelvic organ prolapse. *Int Urogynecol J*. 2024;35(1):85–93. DOI: [10.1007/s00192-023-05653-8](https://doi.org/10.1007/s00192-023-05653-8)

- [16] Zhu H, Zhang D, Gao L, Liu H, Di Y, Xie B, et al. Effect of pelvic floor workout on pelvic floor muscle function recovery of postpartum women: Protocol for a randomized controlled trial. *Int J Environ Res Public Health*. 2022;19(17):11073. DOI: [10.3390/ijerph191711073](https://doi.org/10.3390/ijerph191711073)
- [17] Tateiwa T, Endo K, Matsuoka Y, Ishida T, Shishido T, Yamamoto K. Pelvic tilt after total hip arthroplasty in patients with osteoarthritis of the hip. *J Orthop Surg*. 2020;28(2):2309499020918317. DOI: [10.1177/2309499020918317](https://doi.org/10.1177/2309499020918317)
- [18] Fischer MCM, Tokunaga K, Okamoto M, Habor J, Radermacher K. Preoperative factors improving the prediction of the postoperative sagittal orientation of the pelvis in standing position after total hip arthroplasty. *Sci Rep*. 2020;10:15944. DOI: [10.1038/S41598-020-72782-1](https://doi.org/10.1038/S41598-020-72782-1)
- [19] Tezuka T, Heckmann ND, Bodner RJ, Dorr LD. Functional safe zone is superior to the Lewinnek safe zone for total hip arthroplasty: Why the Lewinnek safe zone is not always predictive of stability. *J Arthroplasty*. 2019;34(1):3–8. DOI: [10.1016/j.arth.2018.10.034](https://doi.org/10.1016/j.arth.2018.10.034)
- [20] Shimizu M., Kobayashi T, Chiba H, Jimbo S, Senoh I, Ito H. Adult spinal deformity and its relationship with hip range of motion: A cohort study of community-dwelling females. *Spine J*. 2019;19(7):1202–9. DOI: [10.1016/J.SPINEE.2019.02.006](https://doi.org/10.1016/J.SPINEE.2019.02.006)
- [21] Ohfuji S, Jingushi S, Kondo K, Takahashi S, Hirota Y. Epidemiology of hip osteoarthritis. *Rinsho Seikei Geka*. 2012;47(4):301–6. DOI: [10.11477/mf.1408102307](https://doi.org/10.11477/mf.1408102307)
- [22] Eslam Pour A, Schwarzkopf R, Patel KP, Anjaria MP, Lazennec JY, Dorr LD. How much change in pelvic sagittal tilt can result in hip dislocation due to prosthetic impingement? A computer simulation study. *J Orthop Res*. 2021;39(12):2604–14. DOI: [10.1002/jor.25022](https://doi.org/10.1002/jor.25022)
- [23] Palit A, King R, Hart Z, Gu Y, Pierrepont J, Elliott MT, Williams M.A. Bone-to-bone and implant-to-bone impingement: A novel graphical representation for hip replacement planning. *Ann Biomed Eng*. 2020;48(4):1354–67. DOI: [10.1007/S10439-020-02451-X](https://doi.org/10.1007/S10439-020-02451-X)
- [24] Okamoto M, Kawasaki M, Okura T, Seki T, Imagama S. Effects of body mass index and range of motion on intraoperative change in pelvic tilt during total hip arthroplasty using the direct anterior approach. *BMC Musculoskelet Disord*. 2021;22(1):240. DOI: [10.1186/s12891-021-04087-x](https://doi.org/10.1186/s12891-021-04087-x)
- [25] Choe H, Kobayashi N, Kobayashi D, Watanabe S, Abe K, Tezuka T, et al. Postoperative excessive external femoral rotation in revision total hip arthroplasty is associated with muscle weakness in iliopsoas and gluteus medius and risk for hip dislocation. *J Orthop Surg Res*. 2021;16:582. DOI: [10.1186/s13018-021-02744-4](https://doi.org/10.1186/s13018-021-02744-4)
- [26] Premkumar A, Almeida B, Ranawat CS, Jerabek SA, Esposito CI, Mayman DJ. Variability of pelvic axial rotation in patients undergoing total hip arthroplasty. *Hip Int*. 2021;31(2):215–22. DOI: [10.1177/1120700019889618](https://doi.org/10.1177/1120700019889618)
- [27] Grammatopoulos G, Innmann M, Phan P, Bodner R, Meermans G. Spinopelvic challenges in primary total hip arthroplasty. *EFORT Open Rev*. 2023;8(5):298–12. DOI: [10.1530/EOR-23-0049](https://doi.org/10.1530/EOR-23-0049)
- [28] Kobayashi N, Higashihira S, Kitayama H, Kamono E, Yukizawa Y, Oishi T, et al. Effect of decreasing the anterior pelvic tilt on range of motion in femoroacetabular impingement: A computer-simulation study. *Orthop J Sports Med*. 2021;9(4):2325967121999464. DOI: [10.1177/2325967121999464](https://doi.org/10.1177/2325967121999464)

Вплив нахилу таза на зміну центра ротації кульшового суглоба в передопераційному плануванні

Олександр Зубков

Аспірант

Інститут травматології та ортопедії Національної академії медичних наук України

01601, вул. Бульварно-Кудрявська, 27, м. Київ, Україна

<https://orcid.org/0009-0002-6763-5062>

Віктор Торчинський

Доктор медичних наук, старший науковий співробітник

Інститут травматології та ортопедії Національної академії медичних наук України

01601, вул. Бульварно-Кудрявська, 27, м. Київ, Україна

<https://orcid.org/0000-0003-4818-9511>

Анотація. Зростаюча кількість ендопротезувань кульшового суглоба, пов'язана зі старінням населення, вимагає більш точних та ефективних методик планування операцій, щоб забезпечити успішність втручань і мінімізувати ризик ускладнень. Дослідження мало на меті показати, як зміна кута нахилу таза впливає на точне визначення центру ротації кульшового суглоба. У науковій роботі були використані сухі кістки таза та стегнової кістки з імплантованою сталевною кулькою діаметром 4 мм у голівці стегнової кістки для моделювання. Рентгенівські знімки виконувались за допомогою Рентген апарату PLX 140 для фіксації зміщення центру ротації. Дослідження підтвердило гіпотезу про те, що зміна кута нахилу таза призводить до зміщення центру ротації кульшового суглоба. Таке зміщення вимагає уваги при передопераційному плануванні, оскільки може вплинути на вибір та розміщення ендопротеза. Дослідження виявило, що великий кут нахилу таза ускладнює встановлення протеза кульшового суглоба, підвищуючи ризики зносу протеза та дислокацій. Це вимагає індивідуалізованого підходу до кожного пацієнта, використання спеціальних імплантатів та післяопераційного спостереження. Необхідно оцінювати антеверсію та інклінацію протеза, регулювати глибину імплантації та вибирати відповідні типи протезів, виходячи з анатомії пацієнта. Використання 3D-моделювання допомагає оптимізувати розміщення протеза. Врахування анатомічних особливостей є ключовим для зниження ризику ускладнень та покращення довгострокових результатів ендопротезування

Ключові слова: ендопротезування; анатомічні параметри; старіння населення; якість лікування; довгострокові результати; оптимізація хірургії; ризик ускладнень