

©D. M. Zhelezov¹, T. O. Savenko²

¹Odesa National Medical University

²Odesa Regional Pathoanatomical Bureau

UTERINE SCAR FORMATION AND EXPRESSION OF SPECIFIC CONNECTIVE TISSUE PROTEINS

The aim of the study – to evaluate the role of expression of specific connective tissue proteins in the formation of the scar on the uterus.

Materials and Methods. The study was performed on the basis of the regional perinatal center and KU PB No. 5 during 2017–2019. 426 women with a scar on the uterus were examined, including 115 (27.0 %) with two or more scars. The mean age of the subjects was (33.4±1.1) years. The results of sonographic studies were analyzed. For pathomorphological examination, three cases of intranatal rupture of the uterine wall along the “old” scar after cesarean section from middle-aged women with a gestational age of 33 to 40 weeks are presented. The expression of collagen types 1 and 3 and the protein of the intermediate filaments of the muscle tissue of desmin was determined using a semi-quantitative method with the calculation of H-score.

Results and Discussion. Analysis of ultrasound data showed that the average assessment of the degree of insolvency of the scar on the uterus was in the examined women $X=(1.3\pm 0.2)$ points, a high level of insolvency was found in 114 (26.8 %) pregnant women. At the same time, 225 (52.8 %) pregnant women showed no signs of scar failure at all. In 87 (20.4 %) one sign of uterine scar failure was found, in 76 (17.8 %) – two signs, in 20 (4.7 %) – three signs, and in 18 (4.2 %) – four signs. Subsequently, 44 (10.3 %) women were born operatively, the rest gave birth per via naturales. Local myometrial defect after ultrasound delivery was detected in 25 of 182 (13.7 %) women who gave birth independently.

Conclusions. A high level of scar failure risk is found in 26.8 % of pregnant women. H-score values for collagen types 1 and 3 averaged (212±24) and (188±22), for desmin – (193±17). Thus, reparative processes at the site of previous surgery on the uterine wall are by incomplete regeneration (substitution) and compensatory hyperplasia of structural tissue elements.

Key words: uterine scar; diagnosis; prognosis; pathomorphology.

ФОРМИРОВАНИЕ РУБЦА НА МАТКЕ И ЭКСПРЕССИЯ СПЕЦИФИЧЕСКИХ БЕЛКОВ СОЕДИНИТЕЛЬНОЙ ТКАНИ

Цель исследования – оценить роль экспрессии специфических белков соединительной ткани в формировании рубца на матке.

Материалы и методы. Исследование выполнено на базе областного перинатального центра и КУ ПБ № 5 в течение 2017–2019 годов. Обследовано 426 женщин с рубцом на матке, в том числе 115 (27,0 %) – с двумя и более рубцами. Средний возраст обследованных составил (33,4±1,1) года. Анализовали результаты сонографических исследований. Для патоморфологического исследования представлены три случая интранатальных разрывов стенки матки по «старому» рубцу после операции кесарева сечения от женщин среднего возраста со сроком гестации от 33 до 40 недель. Определяли экспрессию коллагенов 1 и 3 типов и протеина промежуточных филаментов мышечной ткани десмина с помощью количественного метода с расчетом H-score.

Результаты исследования и их обсуждение. Анализ данных УЗИ показал, что средняя оценка степени несостоятельности рубца на матке составила у обследованных женщин $X=(1,3\pm 0,2)$ балла, высокий уровень несостоятельности был обнаружен в 114 (26,8 %) беременных. В то же время в 225 (52,8 %) беременных признаков несостоятельности рубца вообще обнаружено не было. В 87 (20,4 %) был обнаружен один признак несостоятельности рубца матки, в 76 (17,8 %) – два признака, у 20 (4,7 %) – три признака, а у 18 (4,2 %) – четыре признака. В дальнейшем 44 (10,3 %) пациентки были родоразрешены оперативно, остальные рожали per via naturales. Локальный дефект миометрия после родов на УЗИ определялся у 25 из 182 (13,7 %) женщин, которые рожали самостоятельно.

Выводы. Высокий уровень несостоятельности рубца установлен у 26,8 % беременных. Значения H-score для коллагена 1 и 3 типов составили в среднем 212±24 и 188±22, для десмина – 193±17. Таким образом, репаративные процессы в месте предварительного оперативного вмешательства на стенке матки идут по пути неполной регенерации (субституции) и компенсаторной гиперплазии структурных элементов тканей.

Ключевые слова: рубец на матке; диагностика; прогнозирование; патоморфология.

ФОРМУВАННЯ РУБЦА НА МАТЦІ ТА ЕКСПРЕСІЯ СПЕЦИФІЧНИХ БІЛКІВ СПОЛУЧНОЇ ТКАНИНИ

Мета дослідження – оцінити роль експресії специфічних білків сполучної тканини у формуванні рубця на матці.

Матеріали та методи. Дослідження виконано на базі обласного перинатального центру та КУ ПБ № 5 впродовж 2017–2019 років. Обстежено 426 жінок з рубцем на матці, в тому числі 115 (27,0 %) – з двома та більше рубцями. Середній вік обстежених склав (33,4±1,1) року. Анализували результати сонографічних досліджень. Для патоморфологічного дослідження представлено три випадки інтранатальних розривів стінки матки по «старому» рубцю після операції кесаревого розтину від жінок середнього віку зі строком гестації від 33 до 40 тижнів. Визначали експресію колагенів 1 і 3 типів та протеїну проміжних філаментів м'язової тканини десміну за допомогою напівкількісного методу з розрахунком H-score.

Результати дослідження та їх обговорення. Аналіз даних УЗД показав, що середня оцінка ступеня неспроможності рубця на матці склала в обстежених жінок $X=(1,3\pm 0,2)$ бала, високий рівень неспроможності був виявлений у 114 (26,8 %) вагітних. Водночас у 225 (52,8 %) вагітних ознак неспроможності рубця взагалі виявлено не було. У 87 (20,4 %) спостере-

жено одну ознаку неспроможності рубця матки, у 76 (17,8 %) – дві ознаки, у 20 (4,7 %) – три ознаки, а у 18 (4,2 %) – чотири ознаки. У подальшому 44 (10,3 %) пацієнтки були розроджені оперативно, решта народжувала per via naturales. Локальний дефект міометрія після пологів на УЗД визначався у 25 з 182 (13,7 %) жінок, які народжували самостійно.

Висновки. Високий рівень неспроможності рубця виявлено у 26,8 % вагітних. Значення H-score для колагену 1 та 3 типів склали в середньому 212 ± 24 та 188 ± 22 , для десміну – 193 ± 17 . Таким чином, репаративні процеси у місці попереднього оперативного втручання на стінці матки йдуть шляхом неповної регенерації (субституції) та компенсаторної гіперплазії структурних елементів тканин.

Ключові слова: рубець на матці; діагностика; прогнозування; патоморфологія.

Scar formation is a physiological response to tissue damage. Many scientific works have been devoted to the issues of wound healing. The scar is formed under conditions of close interaction of various cellular and humoral factors, the speed of its formation depends on the state of the extracellular matrix, the metabolic profile of the organism. The functional abilities of myometrium muscle tissue after surgery on the uterus [1, 2, 6, 9] are of particular interest. The presence of a scar on the uterus significantly increases the risk of complications during pregnancy and childbirth [1, 8, 10, 12], so assessing of its ability to hold the *ante et intra partem* load is a very important component of pregnancy management.

A scar on the uterus can form after a caesarean section (in the lower uterine segment and, rarely, the uterine body), after conservative myomectomy before and during pregnancy (either without opening the uterine cavity or with its opening). The scar on the uterus can be a consequence of uterine perforation during intrauterine interventions – abortions, hysteroscopy, as well as other traumatic complications. Also, the scars on the uterus after ectopic pregnancy (in the interstitial section of the fallopian tube, at the junction of the vestigial horn of the uterus with the main uterine cavity, in the cervix after removal of the cervical pregnancy) are described. Sometimes a scar on the uterus is formed after reconstructive plastic surgery (Shtrasman's surgery, removal of the uterine horn rudiment, etc.). Regardless of the type of intervention performed, the formation of the scar on the uterus is associated with the risk of its failure, which alters the endometrium's biomechanics and causes the risk of uterus diastasis and rupture [1–4, 6, 12–15].

In every third woman, signs of functional failure of the scar on the uterus are sonologically determined within a year after surgery [15]. It is believed that after surgery, the processes of repair in the myometrium normally flow due to the regeneration of smooth muscle cells (so-called morphological restitution). In violation of tissue repair by the mechanism of substitution reparative processes with disorganization of both collagen fibrils and intercellular matrix, expressed inflammatory reaction, impaired angiogenesis [4, 6, 8, 9, 12] are observed.

THE AIM OF THE STUDY – to evaluate the role of expression of specific connective tissue proteins in uterine scar formation.

MATERIALS AND METHODS. The research was performed on the basis of the Regional Perinatal Centre and Maternity Home No. 5 (Odesa, Ukraine) during 2017–2019. Under this period 426 women with scar on the uterus were examined, among them 115 (27.0 %) patients had two or more scars. The mean age of the women under examination was (33.4 ± 1.1) years.

The results of sonographic studies were analyzed. The degree of insolency of the scar was determined by the formula:

$$X = \sum k_i$$

where k_i – is a sign of failure, including:

- The thickness of the lower uterine segment (LUS) is less than 2 mm (yes – 1 point, no – 0 points)
- Echogenic heterogeneity of the LUS (yes – 1 point, no – 0 points)
- Absence of areas of local blood flow in radial arteries of LUS (yes – 1 point, no – 0 points)
- Resistance index value (IR) for radial LUS arteries (yes – 1 point, no – 0 points)

When the value of $X \geq 2$ points, the risk of uterine rupture was defined as high.

For pathomorphological examination, three cases of intranatal rupture of the uterine walls along the “old” scar after caesarean section from middle-aged women with gestation term 33–40 weeks, without manifestations of metabolic syndrome, diabetes mellitus, systemic diseases of the connective tissue or other conditions which are potential reparation disruptors are presented.

Myometrial slices were fixed in 10 % neutral formalin solution on phosphate buffer (pH 7.2–7.4) for 24 hours. Wiring, paraffin waxing and preparation of microspecimens were done according to the standard method [7]. Microscopy and photographing of microspecimen were performed on a Carl Zeiss photomicroscope (Germany). During the histological examination, the micromorphological structure of the postoperative scars and the myometrium pericycatrix area was determined. Additionally, immunohistochemical studies were performed on serial paraffin sections of biopsy material using primary and secondary monoclonal antibodies of Dako kits (USA) [11].

To quantify the immunohistochemical results in sections at 400x magnification of the microscope, the number of cells in which immunoperoxidase label (positive staining) was detected in 10 fields of sight, randomly selected (> 200 cells) was counted [7].

The expression of collagen 1 and 3 types and protein of intermediate filaments of muscular tissue of desmin was determined using the H-score semi-quantitative method. The intensity of membrane staining (0, 1+, 2+, or 3+) is determined for each cell in a fixed field. The H-score was calculated as the sum of individual H-scores for each intensity level seen. One method calculates the percentage of cells at each level of staining intensity, and finally, the H-score is assigned using the following formula:

$$[1 \times (\% \text{ cells } 1+) + 2 \times (\% \text{ cells } 2+) + 3 \times (\% \text{ cells } 3+)].$$

The final score, ranging from 0 to 300, gives greater relative weight to the membrane staining of a higher inten-

sity in a given tissue sample. Sampling quantitative data can be considered positive or negative based on a specific discriminatory threshold

Statistical processing of the results was performed by nonparametric methods using Statistica 10.0 software (Dell StatSoft Inc., USA) [5].

RESULTS AND DISCUSSION. The analysis of ultrasound data showed that the average assessment of the degree of scar failure was $X=(1.3\pm 0.2)$ points in the women under examination, a high level of failure was found in 114 (26.8 %) pregnant women (Fig. 1)

At the same time, 225 (52.8 %) of pregnant women showed no signs of scarring at all. 87 (20.4 %) revealed one sign of uterine scar failure, 76 (17.8 %) had two signs, 20 (4.7 %) had three signs, and 18 (4.2 %) – four signs. Subsequently, 44 (10.3 %) women were delivered promptly, the rest gave birth *per via naturales*. Local defect of myometrium after delivery on ultrasound was determined in 25 out of 182 (13.7 %) women who gave birth independently. It looked like a “niche” in myometrium with an intact serous membrane. With standard staining with hematoxylin and eosin, myometrial specimens revealed unevenly expressed parenchymatous myocyte dystrophy, wave-like deformation, and focal fragmentation. Muscle fibers show growth of connective tissue in the form of eosinophilic linear and star-shaped masses, which are located mainly around a large number of sinusoidal thin-walled vessels. Single extravascular lymphocytes are located peripherally from the sclerosis foci. No inflammation was found in the interstitial tissue and vessel walls. In the areas of rupture: against the background of the aforementioned picture, foci of stratification of muscle fibers, microvascular necrotic changes of single myocytes, ruptures of the interconnecting connective

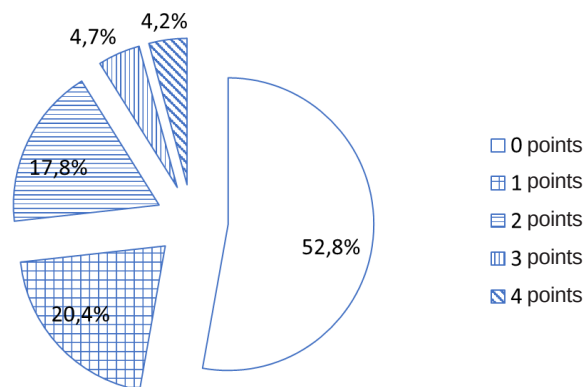


Fig. 1. Frequency of ultrasonoric detection of scar failure signs

tissue (reparative foci) and fields of hemorrhagic seepage was revealed. Reactive inflammatory infiltration was expressed perifocal – non-uniformly, it consisting mainly of lymphocytes and macrophages, where elsewhere of single-celled basophils.

Collagen types I and III in scar tissue were noted to have an uneven content. Basically, collagen I type is contained in the form of fibrillary fractions in the spaces between the bundles of muscle fibers and in the basilar membrane of sinusoidal type thin-walled vessels in the foci of growth of connective tissue (scar tissue). Type III collagen is dominated in membranes of myocytes, fibrocytes, and fibroblasts, and is unevenly contained in the interstitial scar tissue (Fig. 2, a and 2, b).

Depending on the type of prevailing in the connective tissue collagen its density will be different. Thus, fibers

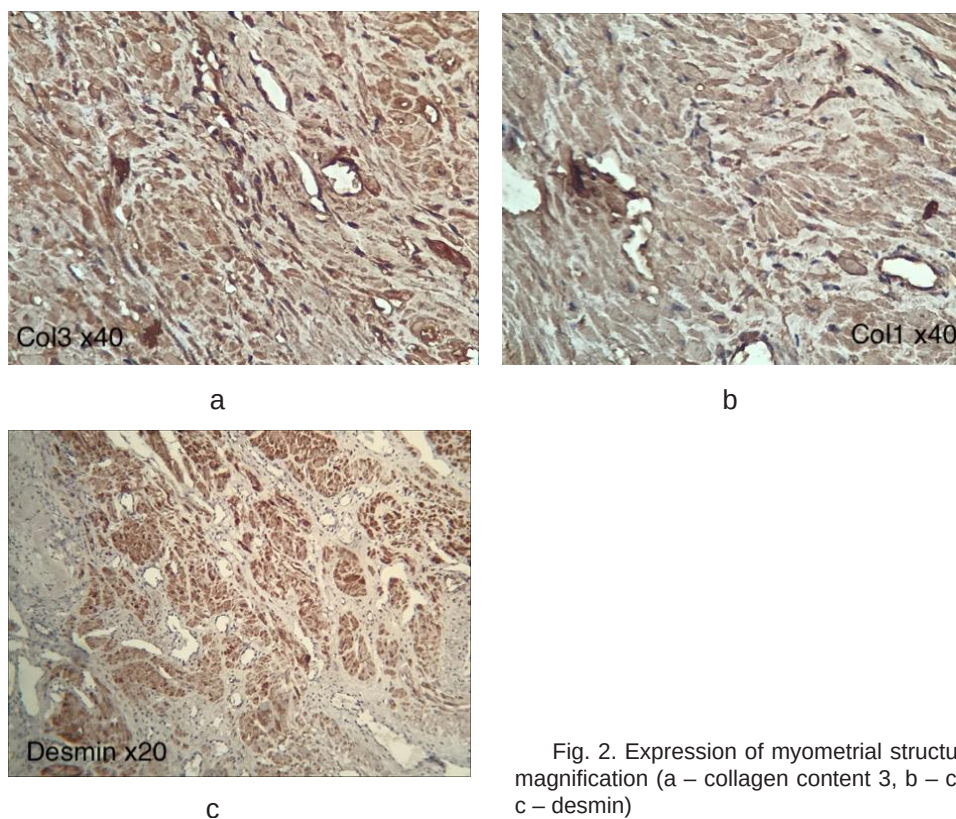


Fig. 2. Expression of myometrial structural proteins. 400X magnification (a – collagen content 3, b – collagen content 1, c – desmin)

formed predominantly of type I collagen are thinner and more arranged, whereas fibers formed from collagen III are coarser and disordered. According to Shlapak I. M. the expression of different types of collagen depends on the degree of traumatization of the fibrous scar tissue. Microbreaks are accompanied by aseptic inflammation with leukocytes migration, including neutrophils and lymphocytes, with the subsequent appearance of fibroblasts, which actually produce type III collagen [6]. In our study, the H-score for collagen I and III types averaged (212±24) and (188±22), respectively, meaning that their expression is almost identical in intensity.

Desmin is an intermediate filament protein located next to the Z-line in myocyte sarcomeres. The increase in its expression indicates that the healing in the postoperative wound goes by way of substitution, i. e. due to the growth of connective tissue with compensatory hyperplasia of

myocytes and muscle fibers. In our study, the H-score for desmin was (193±17).

In the connective tissue of the scar specimen, the muscle fibers lost their unidirectionality and were arranged rather erratically (Fig. 2b). These changes significantly affect the elasticity of the pericyclic areas of the myometrium.

CONCLUSIONS. 1. A high level of scar failure is found in 26.8 % of pregnant women

2. The H-score for collagen types I and III averaged (212±24) and (188±22), for desmin – (193±17).

3. Reparative processes at the site of preoperative surgery on the uterine wall are followed by incomplete regeneration (substitution) and compensatory hyperplasia of tissue structural elements.

THE PROSPECTS FOR FURTHER RESEARCH are linked to the prospective clinical trials on the issues of risk management in pregnancy with uterine scar.

LITERATURE

1. Buyanova S. N. Unstable scar on the uterus after caesarean section: diagnosis, management tactics, reproductive prognosis / S. N. Buyanova, N. V. Puchkova // *Russ. Gazette Obstet.-Gynecol.* – 2011. – Vol. 11, No. 4. – P. 36–38.

2. Vakalyuk L. M. The scar on the uterus after caesarean section on clinical and morphofunctional analysis / L. M. Vakalyuk // *Women's Health.* – 2014. – No. 3. – P. 91–93.

3. Goncharuk N. P. Diagnosis of scar failure on the uterus after caesarean section (Literature review) / N. P. Goncharuk, N. R. Kovid // *Women's Health.* – 2016. – No. 7. – P. 171–173.

4. Morphological studies of the scar on the uterus at caesarean section / L. G. Barashyan, R. S. Lalayan, E. M. Kazmenkova [et al.] // *Ural Sci. Bull.* – 2019. – Vol. 5, No. 3. – P. 12–15.

5. Khalafyan A. L. Probability theory, mathematical statistics and data analysis: Fundamentals of theory and practice on the computer. STATISTICA. EXCEL. More than 150 examples of problem solving / A. L. Khalafyan // *URSC.* – 2016. – 320 p.

6. Shlapak I. M. Clinical-functional and immunohistochemical criteria of urinary scar on the uterus after cesarean section surgery / I. M. Shlapak // *Woman's health.* – 2013. – No. 5 (81). – P. 74–76.

7. Bancroft J. D. Theory and practice of histological techniques / J. D. Bancroft, M. Gamble. 6-ed. – Elsevier, 2008. – 725 p.

8. Brahmakshmy B. L. Variables influencing the integrity of lower uterine segment in post-caesarean pregnancy / B. L. Brahmakshmy, P. Kushtagi // *Arch. Gynecol. Obstet.* – 2015. – Vol. 291 (4). – P. 755–762.

9. Risk factors for incomplete healing of the uterine incision after cesarean section / Y. Chen, P. Han, Y. J. Wang, Y. X. Li // *Arch. Gynecol. Obstet.* – 2017. – Vol. 296 (2). – P. 355–361.

10. Risk of Cesarean scar defect following single- vs double-layer uterine closure: systematic review and meta-analysis of randomized controlled trials / A. Di Spiezo Sardo, G. Saccone, R. McCurdy [et al.] // *Ultrasound Obstet. Gynecol.* – 2017. – Vol. 50 (5). – P. 578–583.

11. Kumar G. L. Immunohistochemical Staining Methods Education Guide. 5th ed / G. L. Kumar, L. Rudbeck – Dako, 2009. – 218 p. [Electronic source]. – Access mode : https://www.agilent.com/cs/library/technicaloverviews/public/08002_ihc_staining_methods.pdf.

www.agilent.com/cs/library/technicaloverviews/public/08002_ihc_staining_methods.pdf.

12. Changes in Cesarean section scar dimensions during pregnancy: a prospective longitudinal study / O. Naji, A. Daemen, A. Smith [et al.] // *Ultrasound Obstet. Gynecol.* – 2013. – Vol. 41 (5). – P. 556–562.

13. Morphology of the cesarean section scar in the non-pregnant uterus after one elective cesarean section / M. Pomorski, T. Fuchs, A. Rosner-Tenerowicz, M. Zimmer // *Ginekol. Pol.* – 2017. – Vol. 88 (4). – P. 174–179.

14. Changes in the uterine scar during the first year after a Caesarean section: A prospective longitudinal study / L. F. van der Voet, I. P. M. Jordans, H. A. M. Brölmann [et al.] // *Gynecol. Obstet. Invest.* – 2018. – Vol. 83 (2). – P. 164–170.

15. A preliminary study of uterine scar tissue following cesarean section / C. Wu, X. Chen, Z. Mei [et al.] // *J. Perinat. Med.* – 2018. – Vol. 46 (4). – P. 379–386.

16. Risager J. K. Cesarean scar thickness in non-pregnant women as a risk factor for uterine rupture / J. K. Risager, N. Ulbjerg, J. Glavind // *J. Matern. Fetal. Neonatal. Med.* – 2020. – P. 1–6. DOI:10.1080/14767058.2020.1719065.

17. Huang L. Clinical efficacy of combined hysteroscopic and laparoscopic surgery and reversible ligation of the uterine artery for excision and repair of uterine scar in patients with type II and III Cesarean scar pregnancy / L. Huang, L. Zhao, H. Shi // *Med. Sci. Monit.* – 2020. – Vol. 26. – P. e924076. DOI:10.12659/MSM.924076.

18. Fox N. S. Pregnancy outcomes in patients with prior uterine rupture or dehiscence: A 5-year update / N. S. Fox // *Obstet. Gynecol.* – 2020. – Vol. 135 (1). – P. 211–212. DOI:10.1097/AOG.0000000000003622.

19. Four surgical strategies for the treatment of Cesarean scar defect: A systematic review and network meta-analysis / Y. He, J. Zhong, W. Zhou [et al.] // *J. Minim. Invasive. Gynecol.* – 2020. – Vol. 27 (3). – P. 593–602. DOI:10.1016/j.jmig.2019.03.027.

20. Donnez O. Cesarean scar defects: management of an iatrogenic pathology whose prevalence has dramatically increased / O. Donnez // *Fertil. Steril.* – 2020. – Vol. 113 (4). – P. 704–716. DOI:10.1016/j.fertnstert.2020.01.037.

REFERENCES

1. Buyanova, S.N., & Puchkova, N.V. (2011). Unstable scar on the uterus after caesarean section: diagnosis, management tactics, reproductive prognosis. *Russ. Gazette Obstet.-Gynecol.*, 11, 4, 36-38.
2. Vakalyuk, L.M. (2014). The scar on the uterus after caesarean section on clinical and morphofunctional analysis. *Women's Health*, 3, 91-93.
3. Goncharuk, N.P., & Kovid, N.R. (2016). Diagnosis of scar failure on the uterus after caesarean section (Literature review). *Women's Health*, 7, 171-173.
4. Barashyan, L.G., Lalayan, R.S., Kazmenkova, E.M., Bondarenko, N.Y., Cherednichenko, A.A., & Kibishev, Z.B. (2019). Morphological studies of the scar on the uterus at caesarean section. *Ural Sci. Bull.*, 5, 3, 12-15.
5. Khalafyan, A.L. (2016). Probability theory, mathematical statistics and data analysis: Fundamentals of theory and practice on the computer. STATISTICA. EXCEL. More than 150 examples of problem solving. URSC.
6. Shlapak, I.M. (2013). Clinical-functional and immunohistochemical criteria of urinary scar on the uterus after cesarean section surgery. *Woman's Health*, 5 (81), 74-76.
7. Bancroft, J.D., & Gamble, M. (2008). *Theory and practice of histological techniques*. 6-ed. Elsevier.
8. Brahmalkshmy, B.L., & Kushtagi, P. (2015). Variables influencing the integrity of lower uterine segment in post-caesarean pregnancy. *Arch. Gynecol. Obstet.*, 291 (4), 755-762.
9. Chen, Y., Han, P., Wang, Y.J., & Li, Y.X. (2017). Risk factors for incomplete healing of the uterine incision after cesarean section. *Arch. Gynecol. Obstet.*, 296 (2), 355-361.
10. Di Spiezio Sardo, A., Saccone, G., McCurdy, R., Bujold, E., Bifulco, G., & Berghella, V. (2017). Risk of Cesarean scar defect following single- vs double-layer uterine closure: systematic review and meta-analysis of randomized controlled trials. *Ultrasound Obstet. Gynecol.*, 50 (5), 578-583.
11. Kumar, G.L., & Rudbeck, L. (2009). *Immunohistochemical Staining Methods Education Guide*. 5th ed. Dako. Retrieved from: https://www.agilent.com/cs/library/technicaloverviews/public/08002_ihc_staining_methods.pdf.
12. Naji, O., Daemen, A., Smith, A., Abdallah, Y., Saso, S., Stalder, C., ..., & Bourne, T. (2013). Changes in Cesarean section scar dimensions during pregnancy: a prospective longitudinal study. *Ultrasound Obstet. Gynecol.*, 41 (5), 556-562.
13. Pomorski, M., Fuchs, T., Rosner-Tenerowicz, A., & Zimmer, M. (2017). Morphology of the cesarean section scar in the non-pregnant uterus after one elective cesarean section. *Ginekol. Pol.*, 88 (4), 174-179.
14. van der Voet, L.F., Jordans, I.P.M., Brölmann, H.A.M., Veersema, S., & Huirne, J.A.F. (2018). Changes in the uterine scar during the first year after a caesarean section: a prospective longitudinal study. *Gynecol. Obstet. Invest.*, 83 (2), 164-170.
15. Wu, C., Chen, X., Mei, Z., Zhou, J., Wu, L., Chiu, W.H., & Xiao, X. (2018). A preliminary study of uterine scar tissue following cesarean section. *J. Perinat. Med.*, 46 (4), 379-386.
16. Risager, J.K., Ulbjerg, N., & Glavind, J. (2020). Cesarean scar thickness in non-pregnant women as a risk factor for uterine rupture. *J. Matern. Fetal. Neonatal. Med.*, 1-6. DOI:10.1080/14767058.2020.1719065.
17. Huang, L., Zhao, L., & Shi, H. (2020). Clinical efficacy of combined hysteroscopic and laparoscopic surgery and reversible ligation of the uterine artery for excision and repair of uterine scar in patients with type ii and iii cesarean scar pregnancy. *Med. Sc.i Monit.*, 26, e924076. DOI:10.12659/MSM.924076.
18. Fox, N.S. (2020). Pregnancy outcomes in patients with prior uterine rupture or dehiscence: a 5-year update. *Obstet. Gynecol.*, 135 (1), 211-212. DOI:10.1097/AOG.0000000000003622.
19. He, Y., Zhong, J., Zhou, W., Zeng, S., Li, H., Yang, H., & Shan, N. (2020). Four surgical strategies for the treatment of cesarean scar defect: a systematic review and network meta-analysis. *J. Minim. Invasive. Gynecol.*, 27 (3), 593-602. DOI:10.1016/j.jmig.2019.03.027.
20. Donnez, O. (2020). Cesarean scar defects: management of an iatrogenic pathology whose prevalence has dramatically increased. *Fertil. Steril.*, 113 (4), 704-716. DOI:10.1016/j.fertnstert.2020.01.037.

Received 05.05.20

Accepted 16.06.20

Address for correspondence: zhelezoff@i.ua